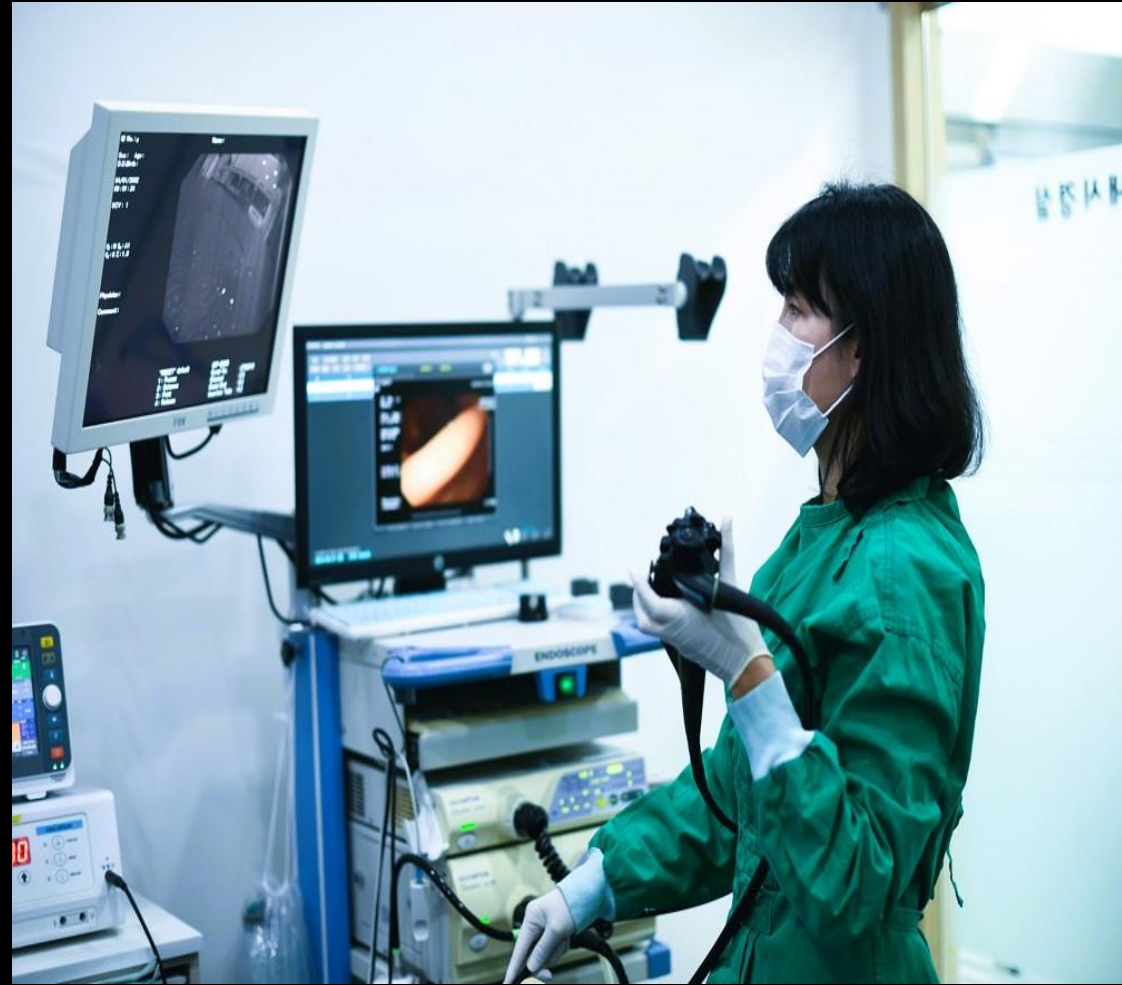


위내시경 검사 의 이해와 기본 술기

연세생명나무내과 소화기내과
전문의 성혜영



내시경 처방- 좋은 소화기 청구책을 따라한다.

☒ 증상(F1)

epigastric soreness, nausea, 속쓰림, 위통,
low abdominal pain
fever -
P/Ex: decreased BS
gas distension
plan) GFS evaluation

☒ 상병(F2) 특정기호체크

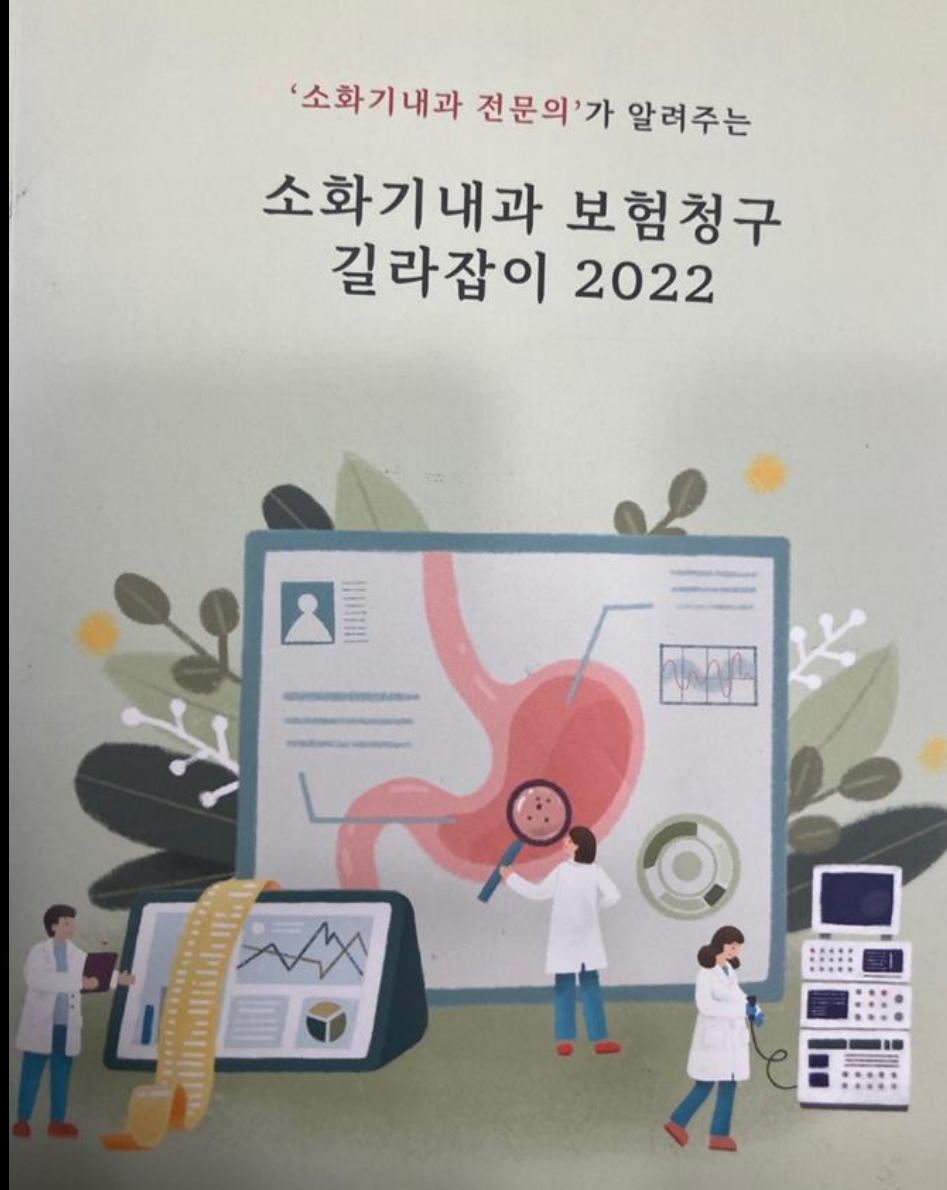
사용자코드	상병명칭	주상병	특정기	의종	수	경과	입원시	입
K2531	출혈 또는 천공이 없는 급성 위...	주상병		<input type="checkbox"/>	수	계속		202
K210	역류식도염	보조상병		<input type="checkbox"/>	수	계속		202

☒ 처방(F3) 초재진 :재진 진료시간 :주간, 11 : 49 ☐ 청구안함

종교	코드	코드명	일투	횟수	일수	청구구분	가격
J	AA254	재진진찰료-의원,보건의료원 내 의과	1.000	1	1	급여	12,590
	E7611	상부소화관내시경검사	1.000	1	1	급여	69,670
	EA010	내시경 세척·소독료	1.000	1	1	급여	15,430
	670604055	히스판주(부틸스코폴라민브롬화물)(수출명·부스판...	1.000	1	1	급여	436
	KK010	피하또는근육내주사	1.000	1	1	급여	1,680
	650100423	베노카인액(염산베독시네이트)_(30mg/10mL)	1.000	1	1	급여	764
	650100021	가소콜액(시메티콘)(균납용 : 시메티콘현탁액500...	10.000	1	1	급여	25
F	AL801	외래환자 의약품관리료-1일분(의원,치과의원,보건...	1.000	1	1	급여	220

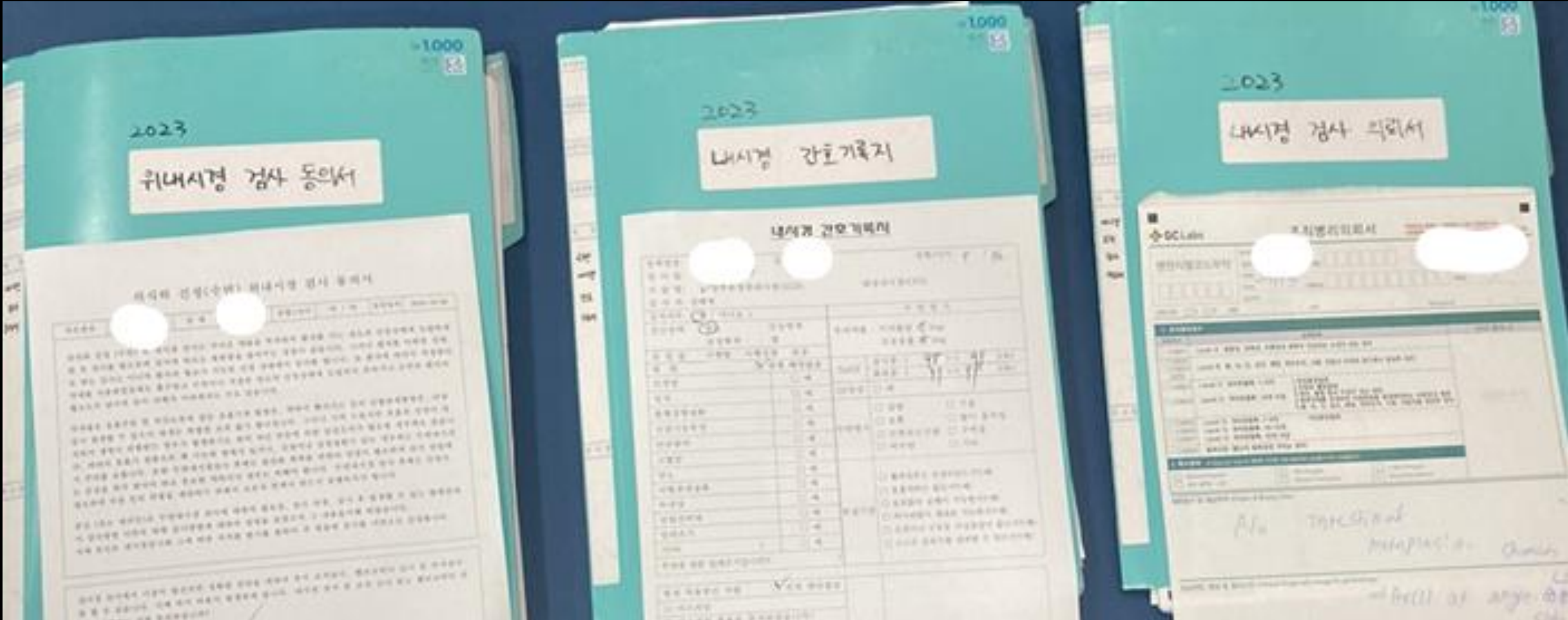
☒ 진료비내역상세

항목	합계	급여		
		본인부담금	공단부담금	전액본인부
진찰료	12,810	3,843	8,967	0
입원료	0	0	0	0
식대	0	0	0	0
[투약]행위료	0	0	0	0
[투약]약품비	1,013	304	709	0
[주사]행위료	1,680	504	1,176	0
[주사]약품비	435	118	317	0
마취료	0	0	0	0
처치 및 수...	0	0	0	0
검사료	85,100	25,530	59,570	0
영상진단	0	0	0	0
방사선치료료	0	0	0	0
치료재료대	0	0	0	0
이학요법료	0	0	0	0
정신요법료	0	0	0	0
전혈/혈액성분	0	0	0	0
CT	0	0	0	0
MRI	0	0	0	0
PET	0	0	0	0
증명료 및...	0	0	0	0
초음파검사료	0	0	0	0
정액환자	0	0	0	0
장애인(지원)	0	0	0	0
포괄수가제	0	0	0	0
선별급여	0	0	0	0
합계	101,040	30,300	70,740	0




내시경 전 준비- 서류작업

검사 동의서, 간호기록지, 조직 검사 의뢰서



목 마취

1. 가소콜(가스제거)
→삼킨다
2. 베노카인 (목 마취)
- 목젓에 물고 있다가
가 뱉어야함.
3. 필요에 따라 리도카인 스프레이도
가능 (급여 안됨)



검사 전 설명

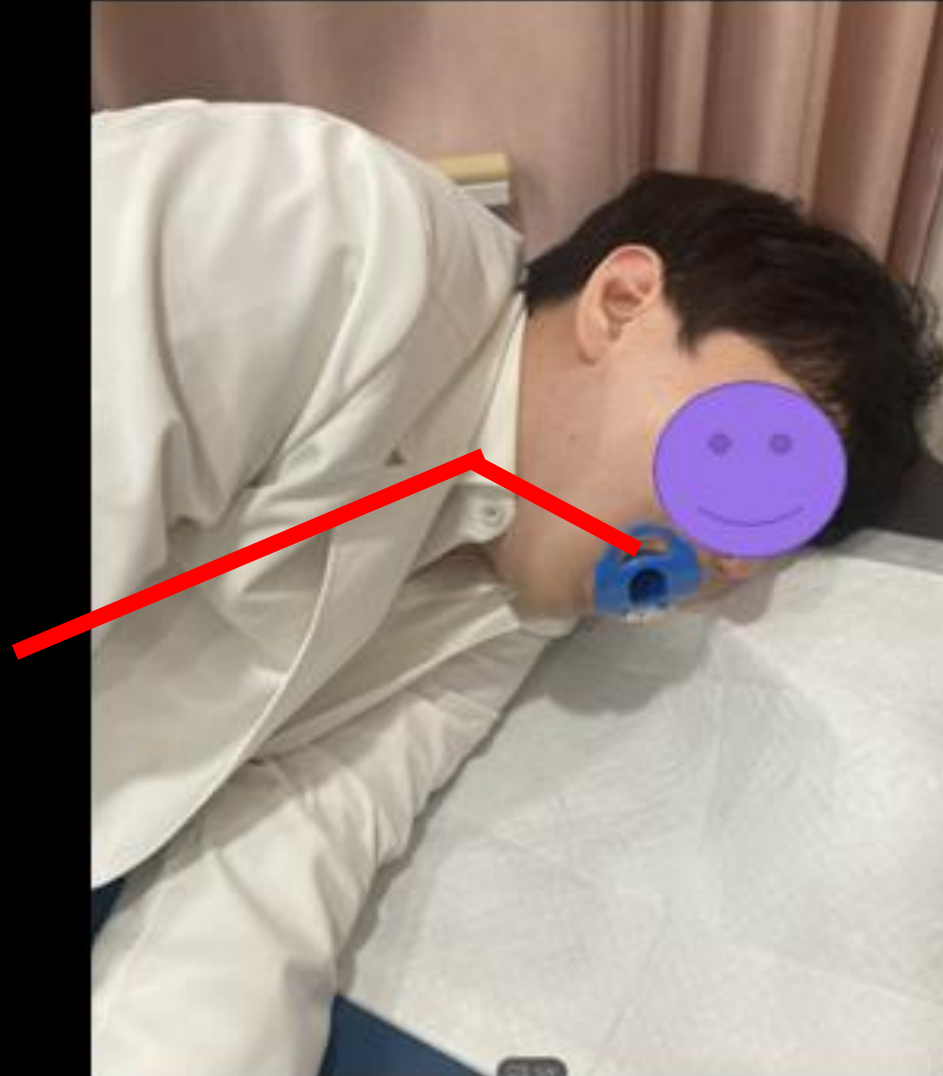
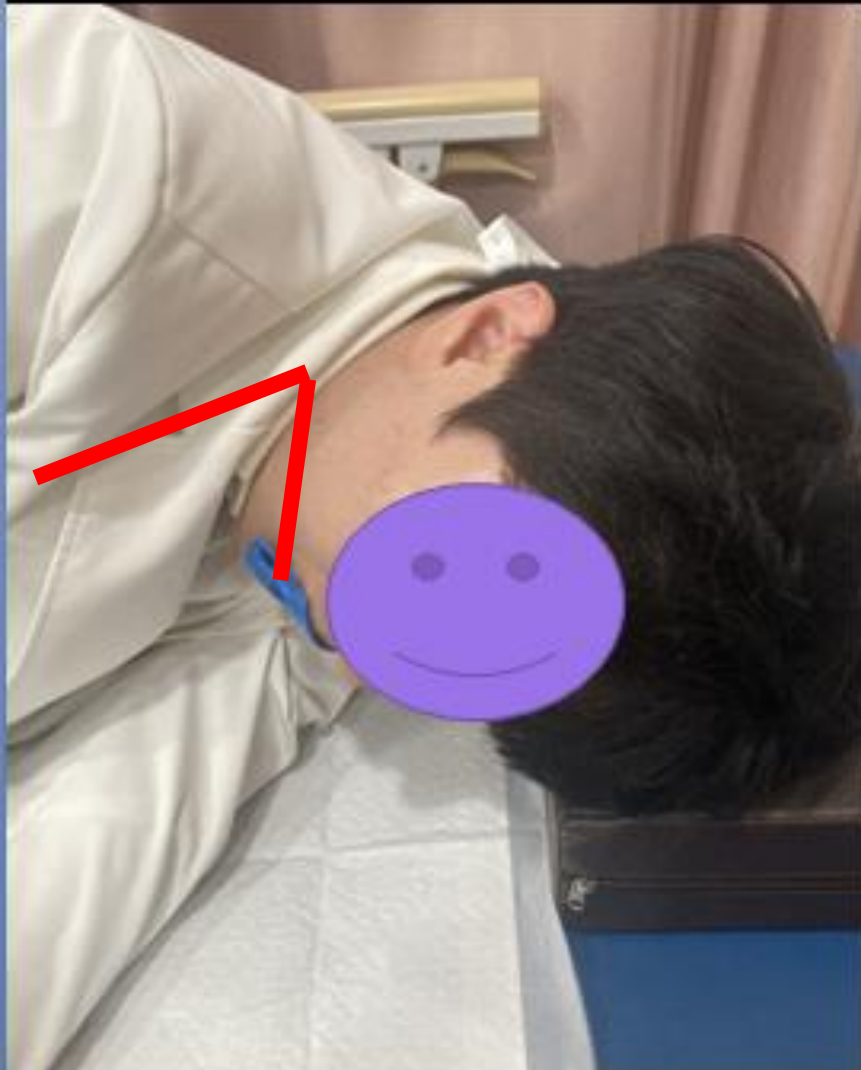
- 입안의 침을 삼키지 말고 흘려 버리십시오
- 가능한 한 트림을 참으십시오
- 어깨와 목에 힘을 빼십시오
- 가능하면 눈을 뜨십시오
- 환자가 잘 협조해 주셔야, 의사가 잘 관찰 할 수 있다.
- 신뢰 관계 형성
- 불안감을 낮춘다

• 불편함과 연관된 요인

- 목을 넘어 갈 때 (40.3%) > 밀어 넣을 때 (38.1%)
- 삽입법: visualization, blind method
- 나이가 어릴 수록, 여성, 처음 내시경 검사
- 검사자의 숙련도

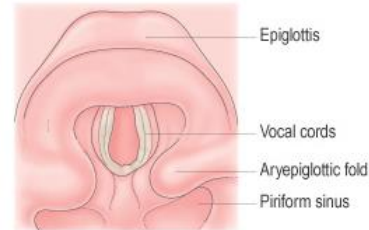
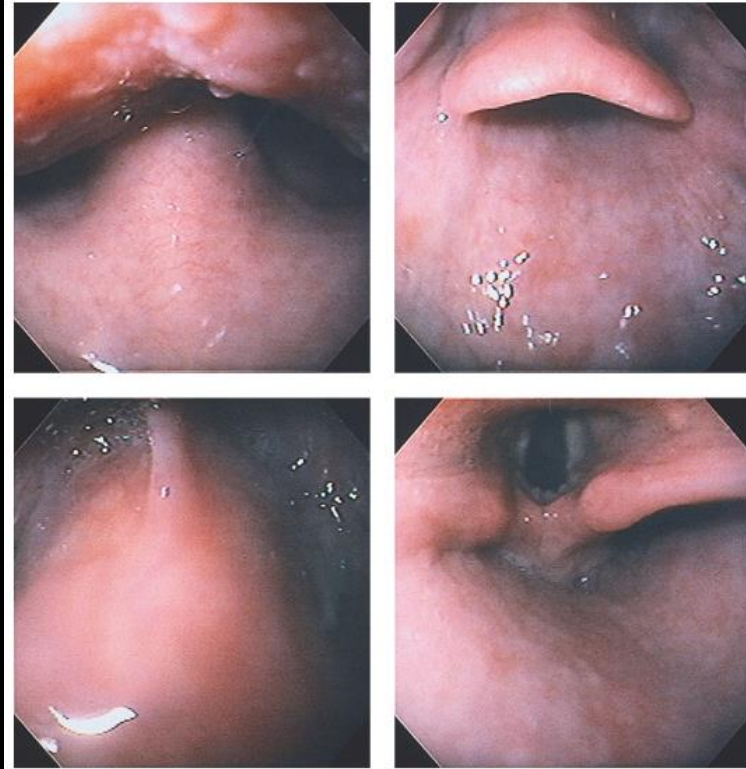
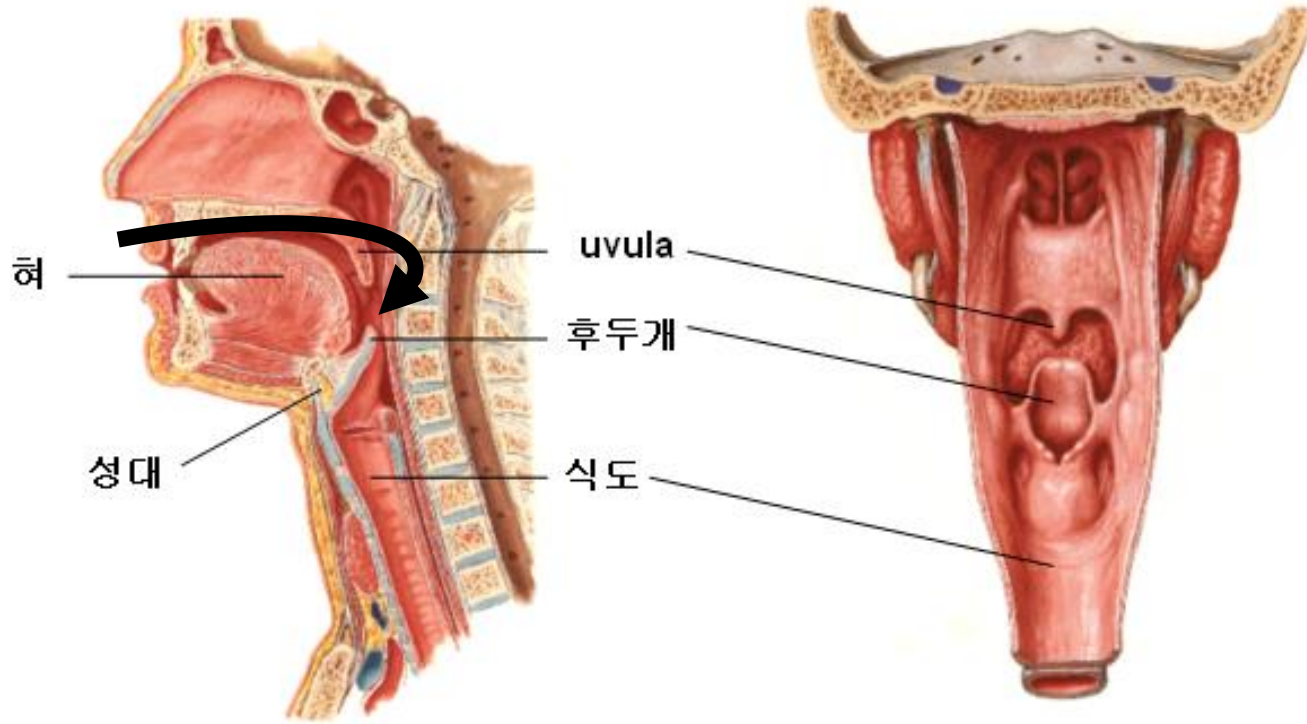


Position 점검



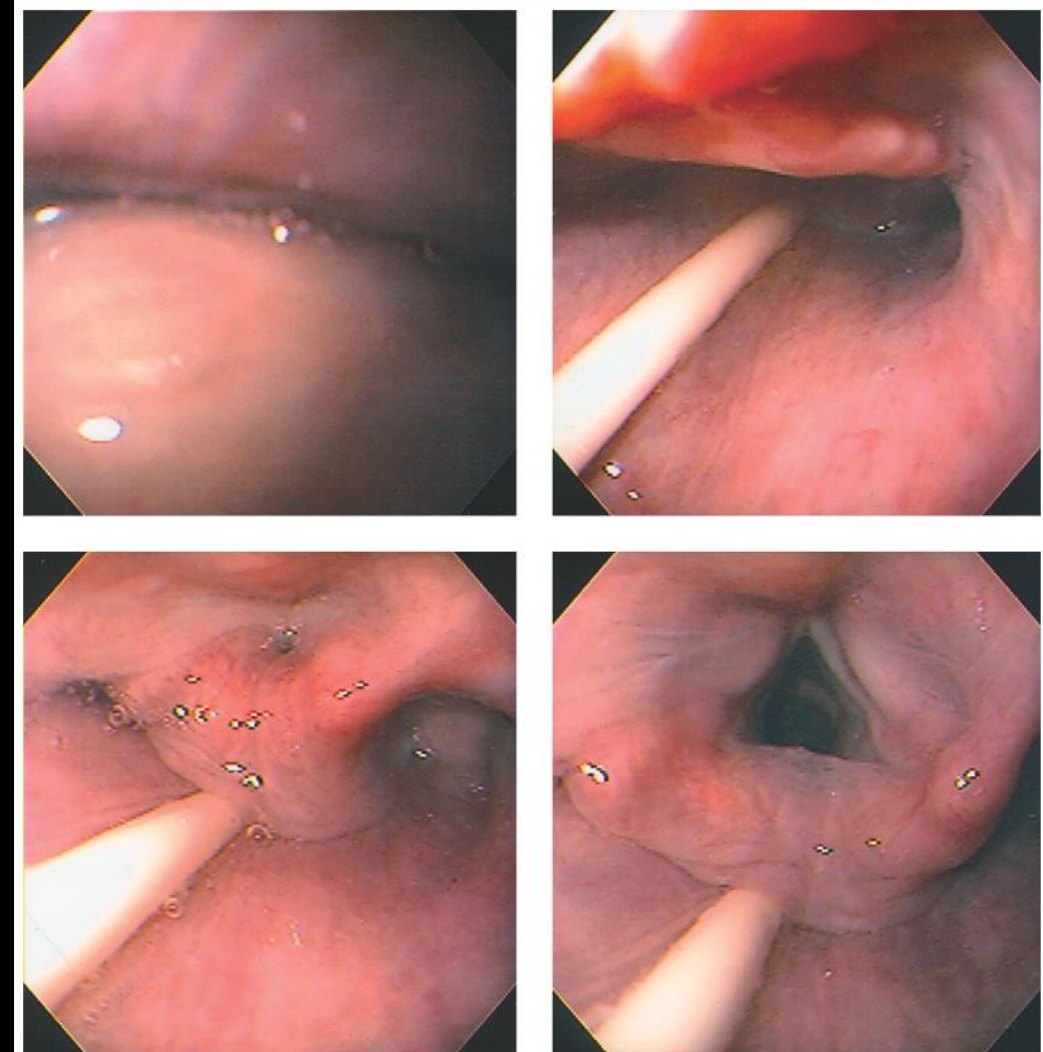
- 목을 구부리면 진입이 힘들다
- 왼쪽 어깨를 안쪽으로 넣어준다

하인두의 해부학적 구조



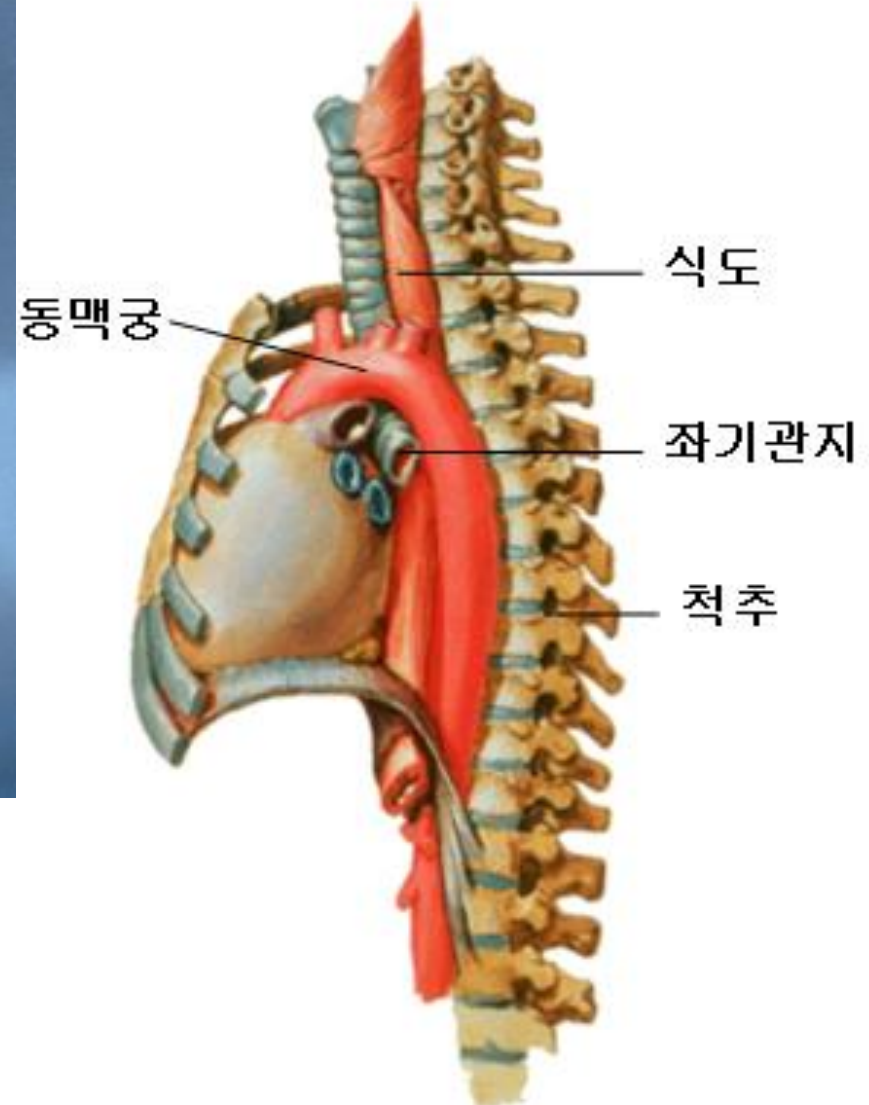
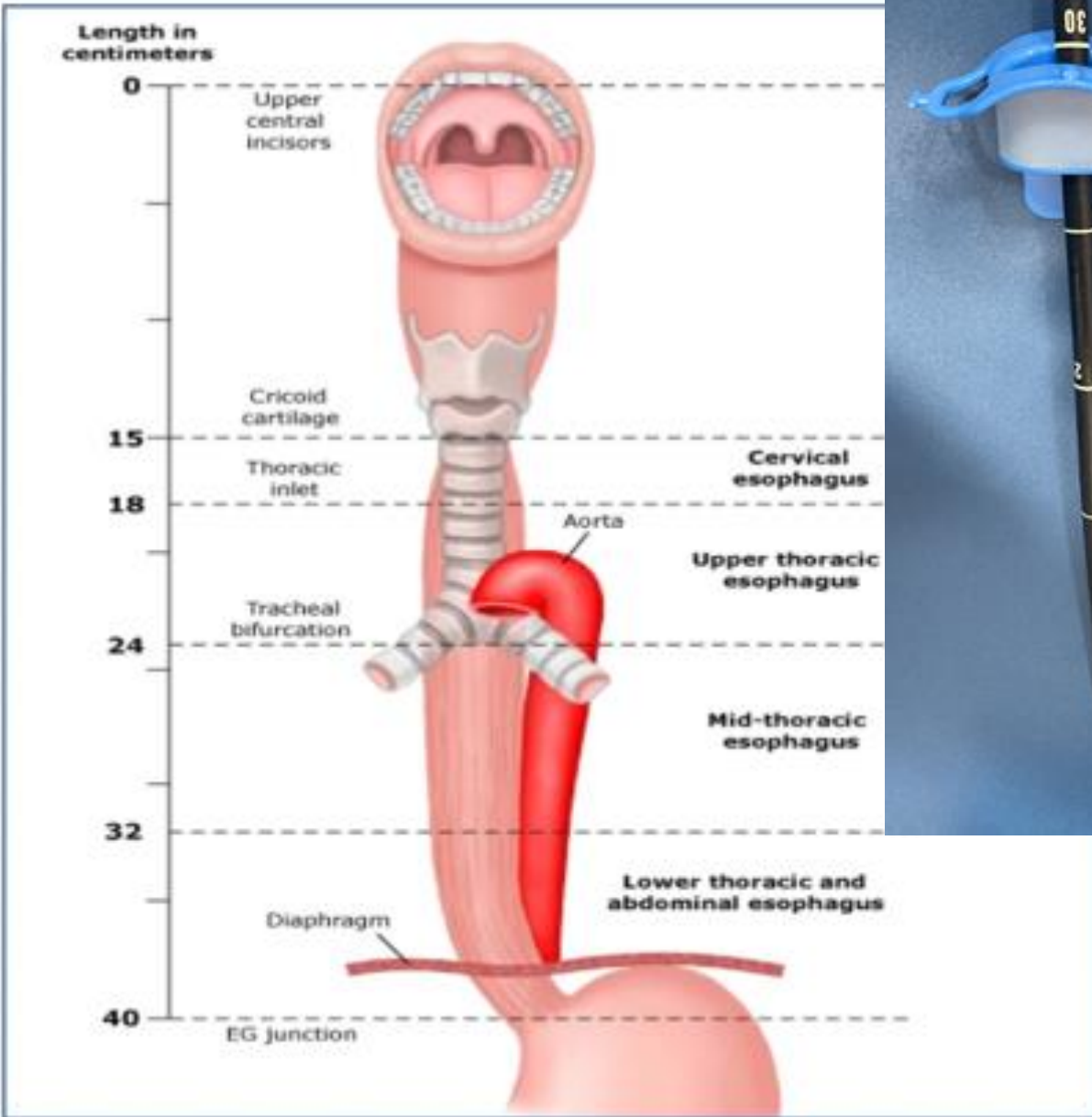
내시경 삽입

- 구강통과시 가능하면 자극 없이 천천히
- scope가 uvula와 epiglottis에 닿지 않도록 한다
- 왼쪽 pyriform sinus에서 중앙으로 밀어 넣는다
- 무리해서 밀어 넣지 않는다
- Larynx, vocal cord 등 주변 구조물도 관찰하는 여유를 갖는다



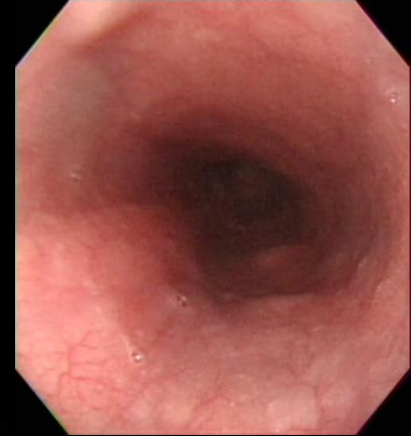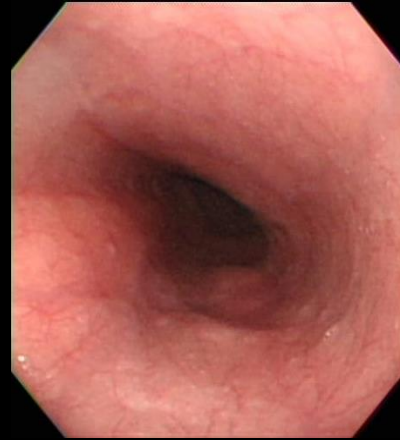
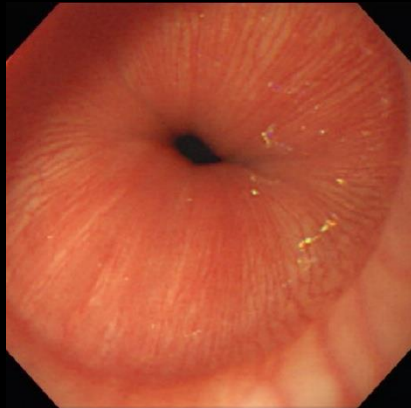
© Elsevier Inc 2007 Wilcox et al: Atlas of Clinical Gastrointestinal Endoscopy 2e.

식도의 해부학



식도 진입

- UES를 통과하면 척추를 6시 방향에 놓는다
- 제 1 협착부 : aortic arch
- 제 2 협착부 : tracheal bifurcation 까지 상부식도
- Left ventricle pulsation
- Incisor 32 cm 까지 중부식도
- Palisade zone
- EG junction



식도병변의 위치에 대한 기재 예

좌측 주기관지

상부식도

중부식도

내시경진단: 진행성 식도암

1) 형태: 2형, 국한 궤양형

(ulcerating and localizing type)

2) 크기 : 3 x 1.5 cm

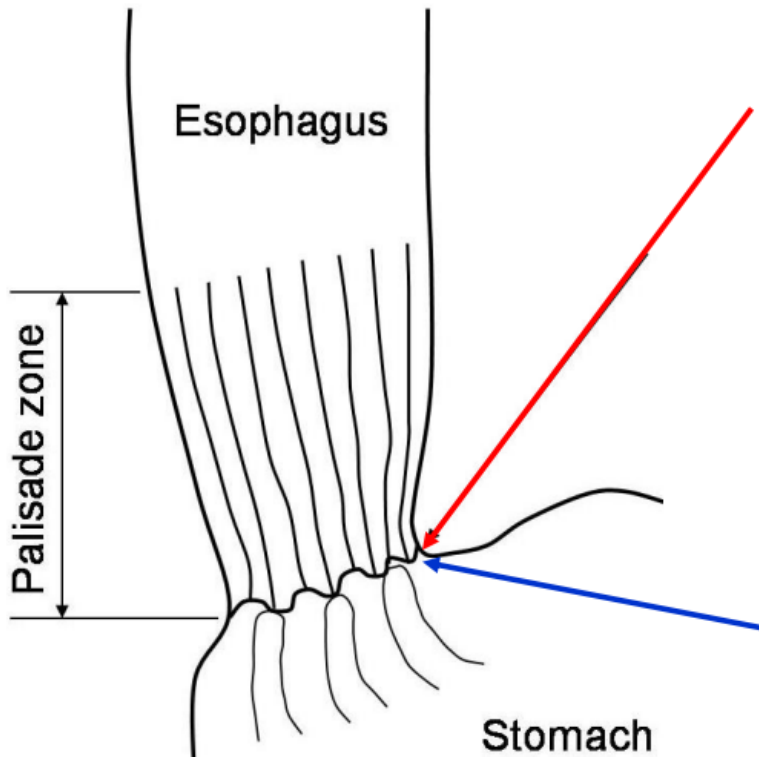
3) 점거부위

중부식도(1m)

절치로부터 28 cm에서 31 cm

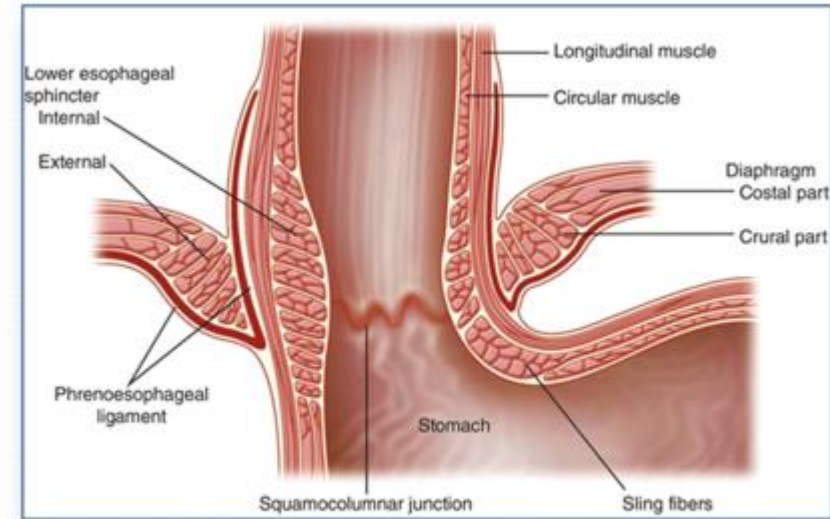
좌 주기관지압박의 반대측 후벽
(5시 부터 7시까지)

식도 하부 해부학적 이해



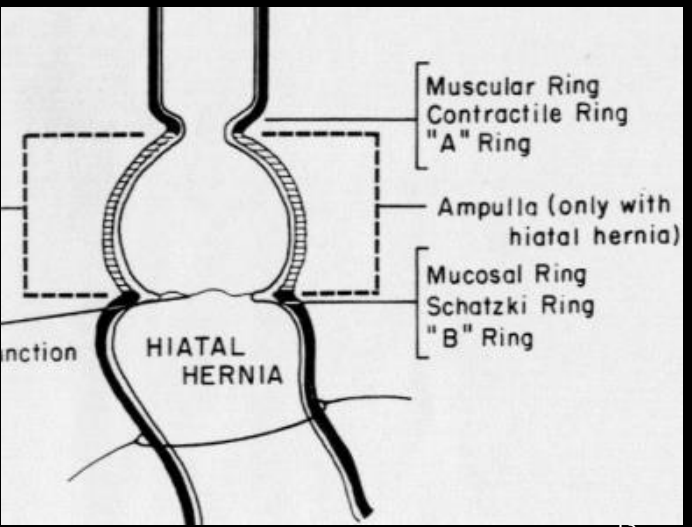
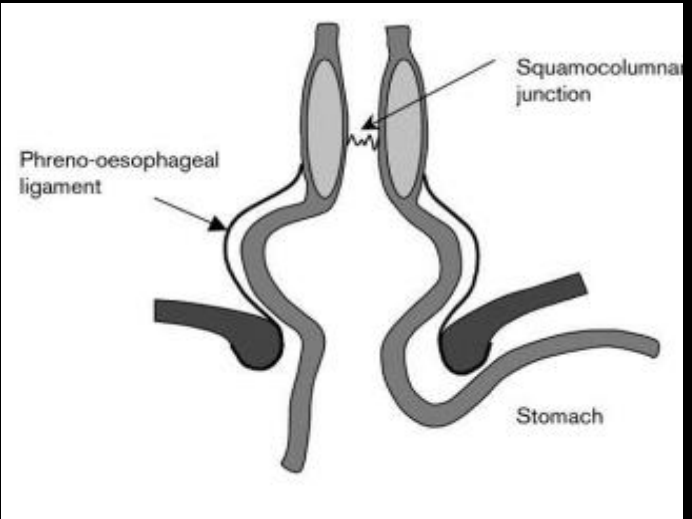
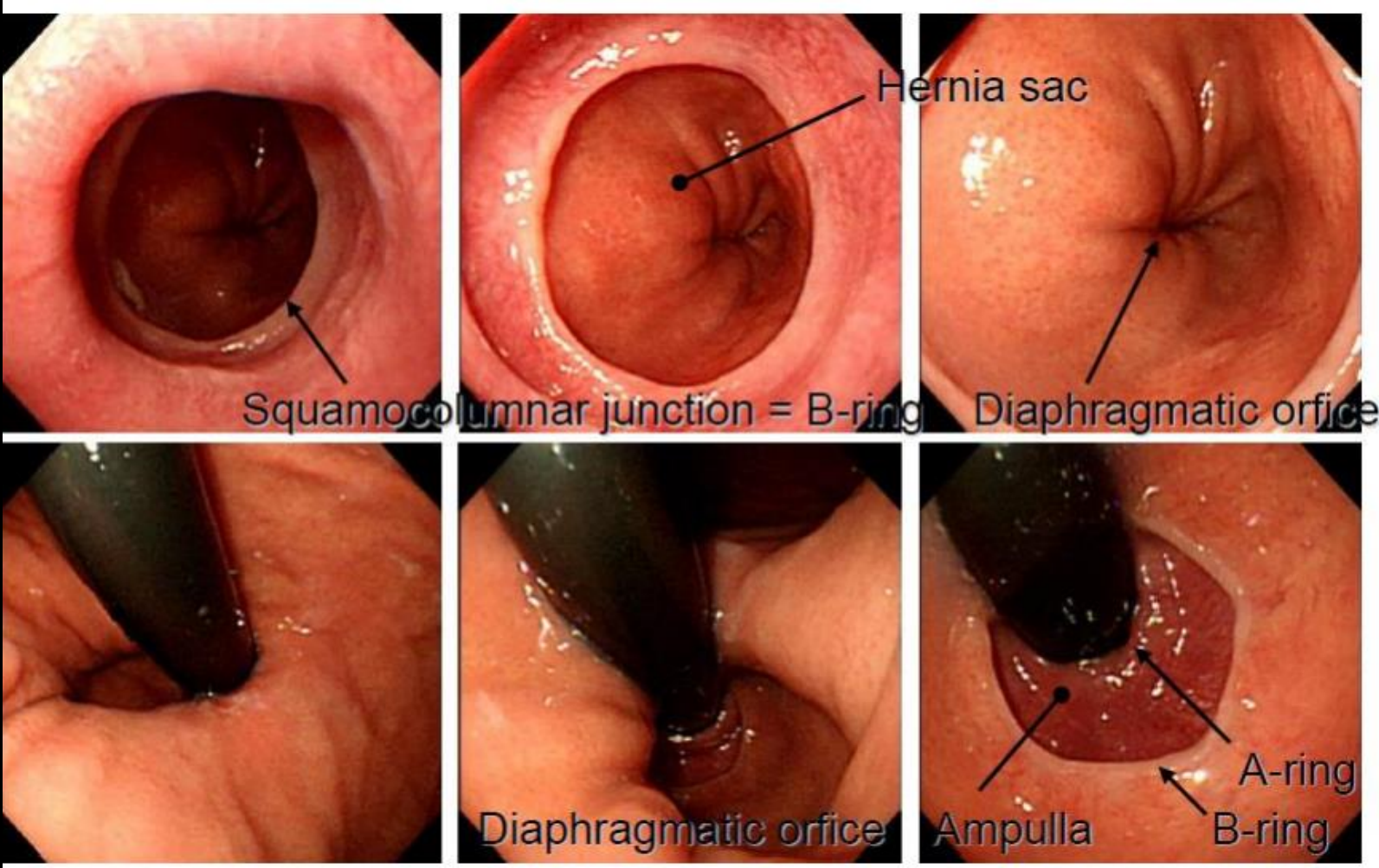
Esophagogastric junction (EGJ)
= Proximal margin of gastric folds
= Distal end of palisade zone

Squamocolumnar junction



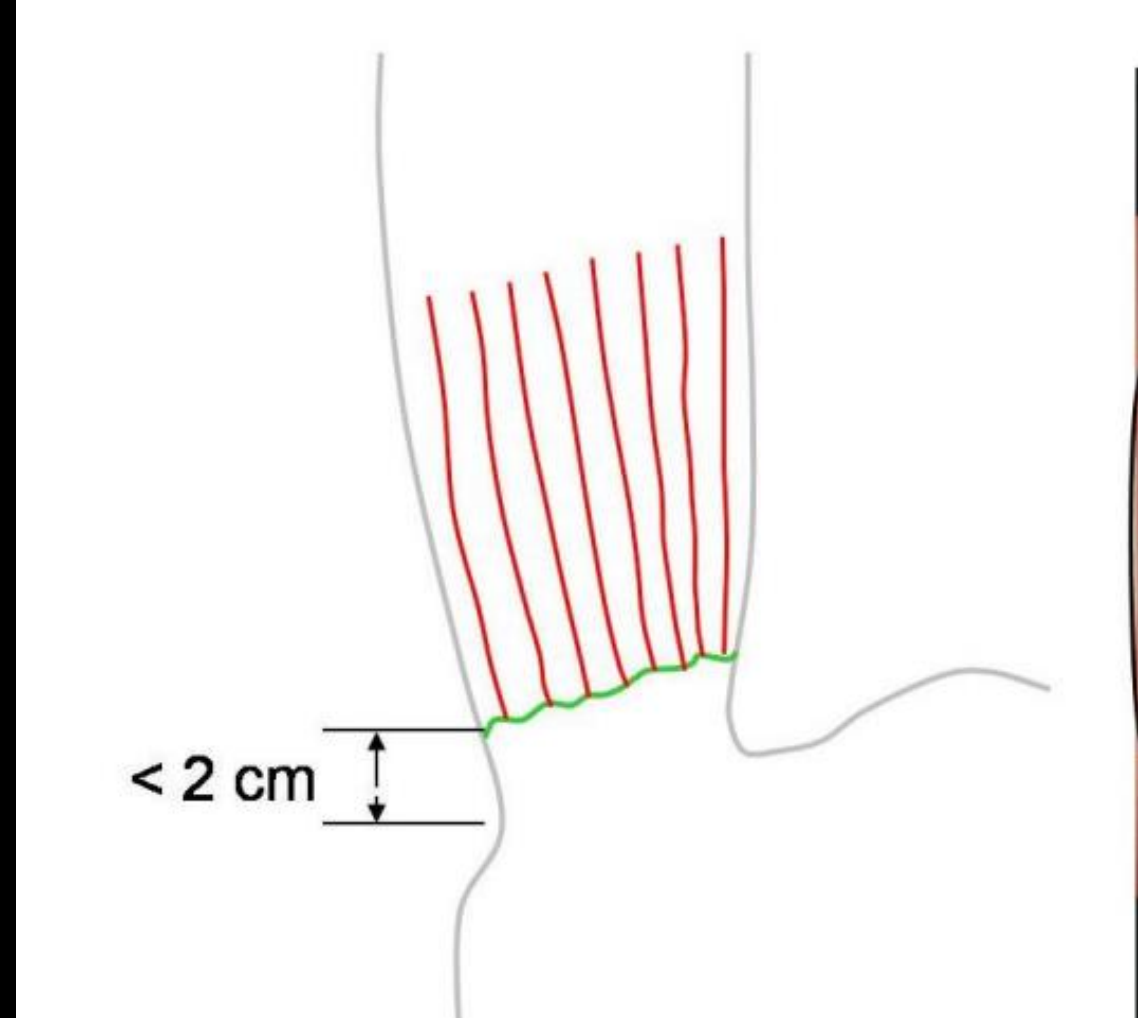
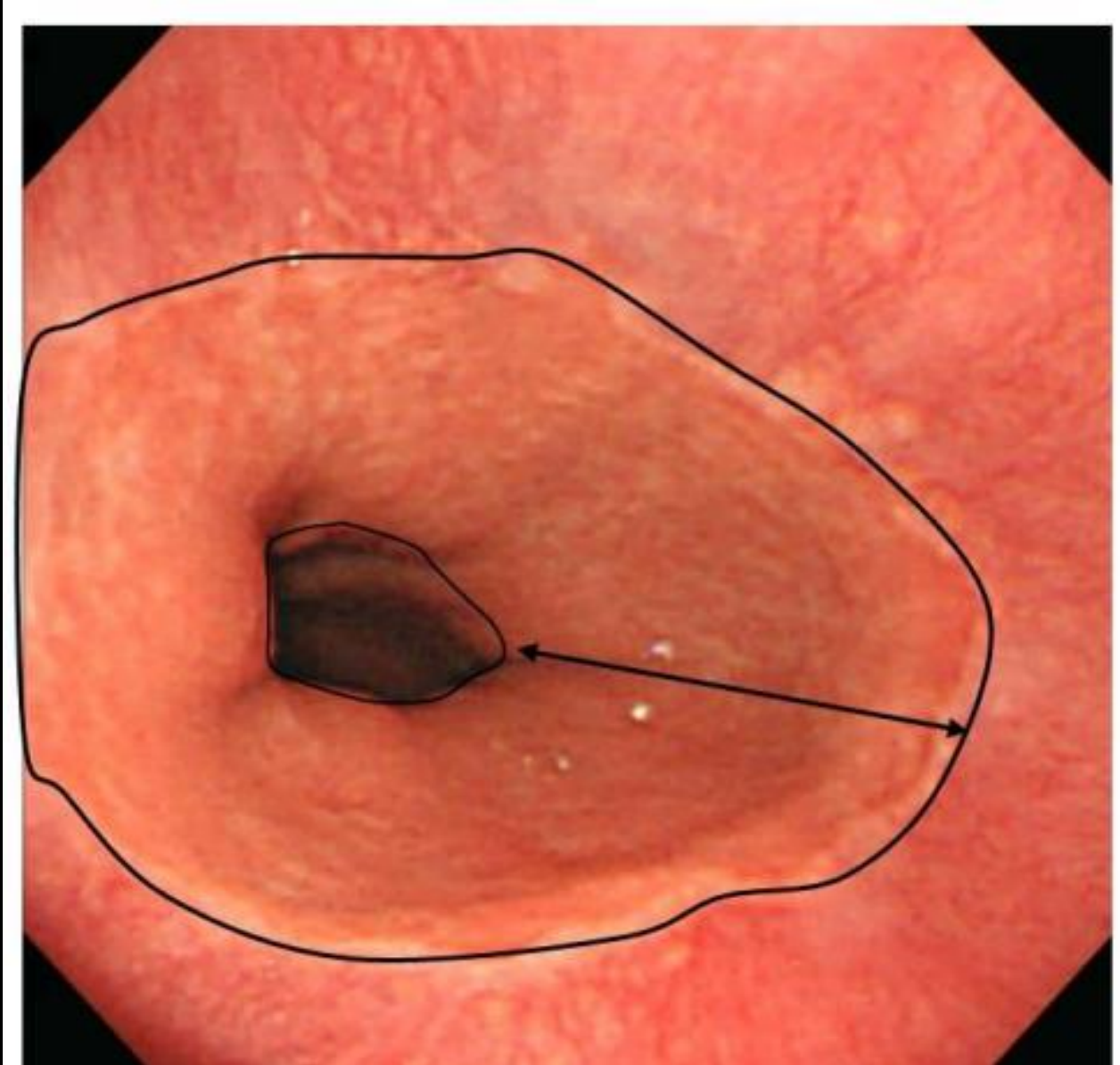
Lower Esophageal Sphincter(출처: www.abdominalkey.com)

식도 열공 Hiatal hernia, type I

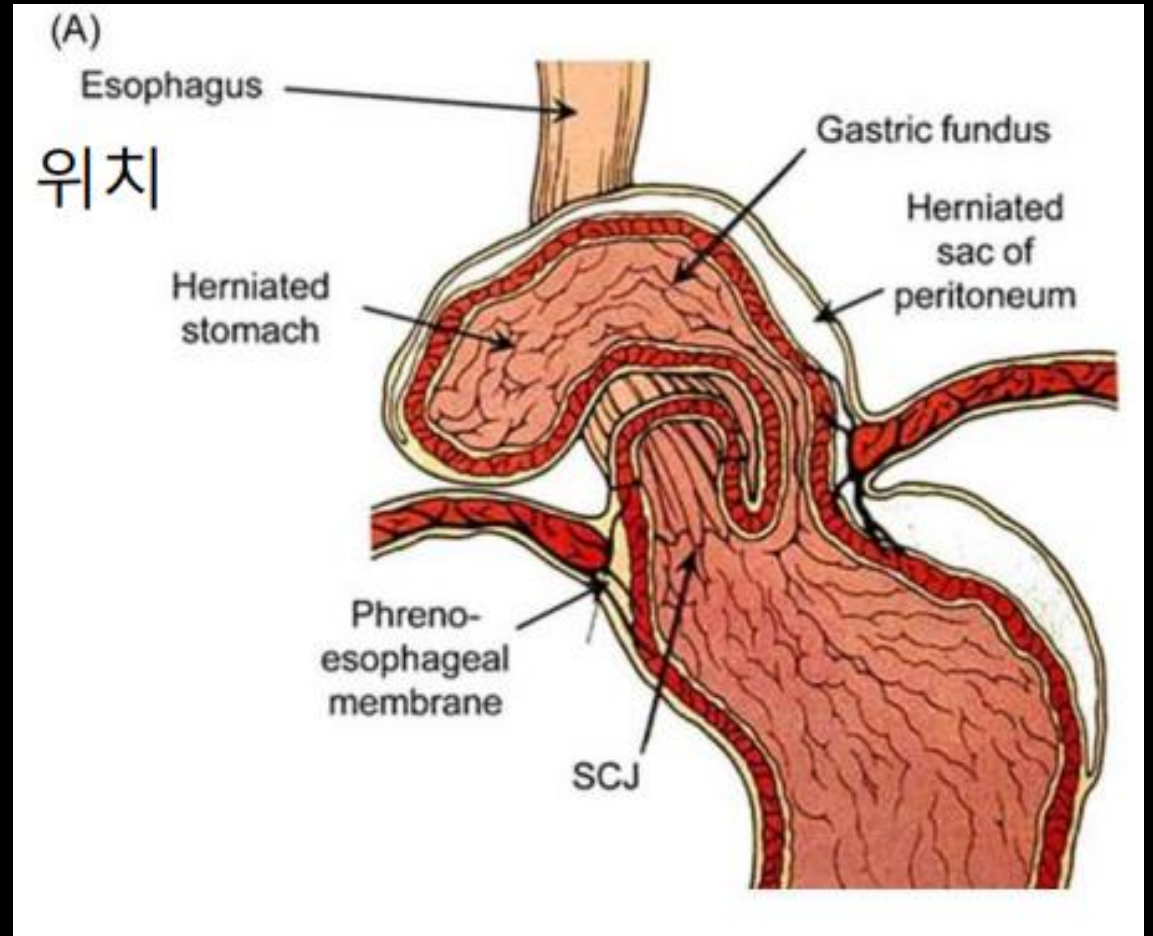
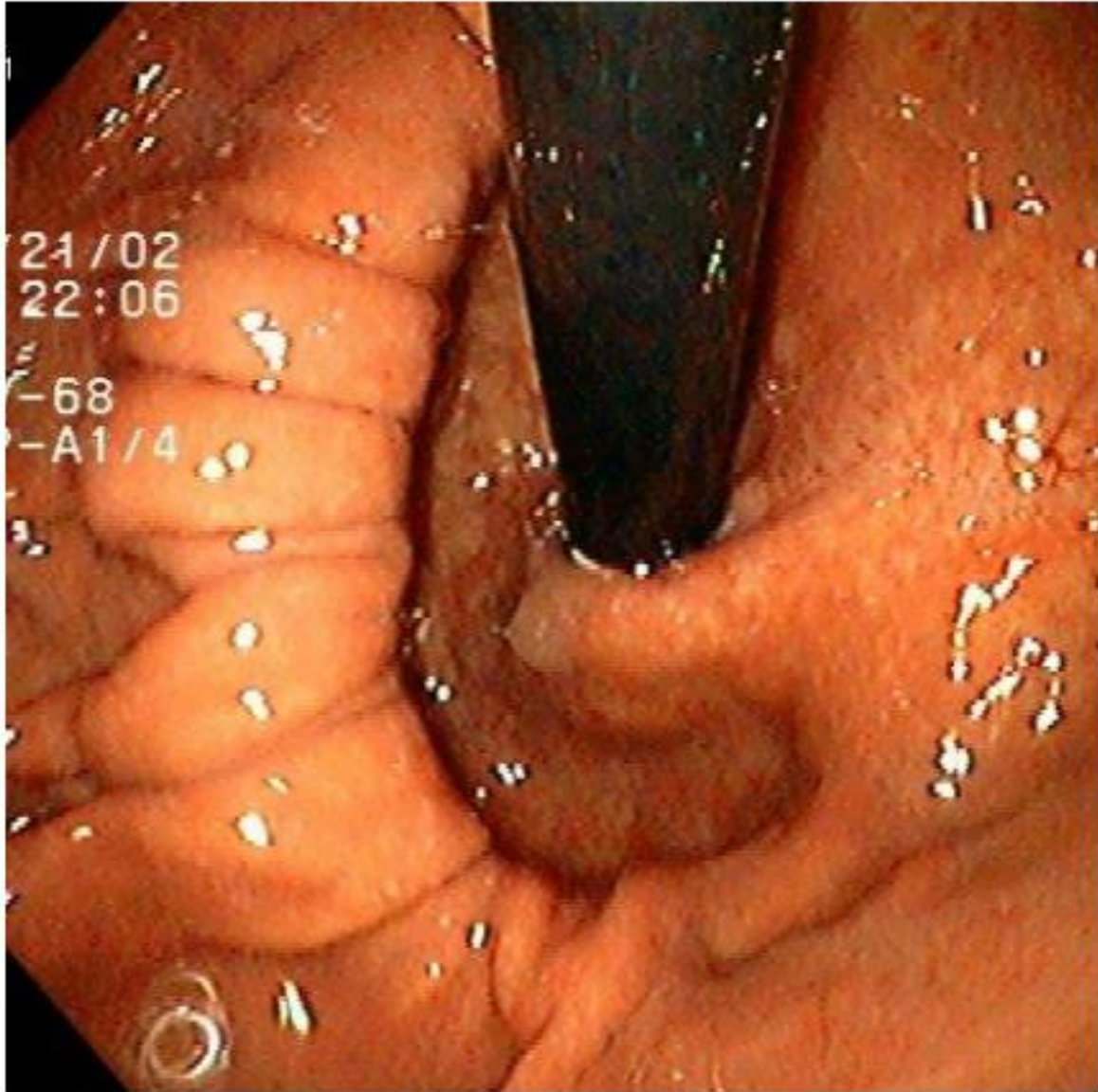


횡경막-식도 인대가 헐거워져 하부식도가 흉강내로 미끄러져 들어감

Short Segment Hiatal Hernia(SSHH)

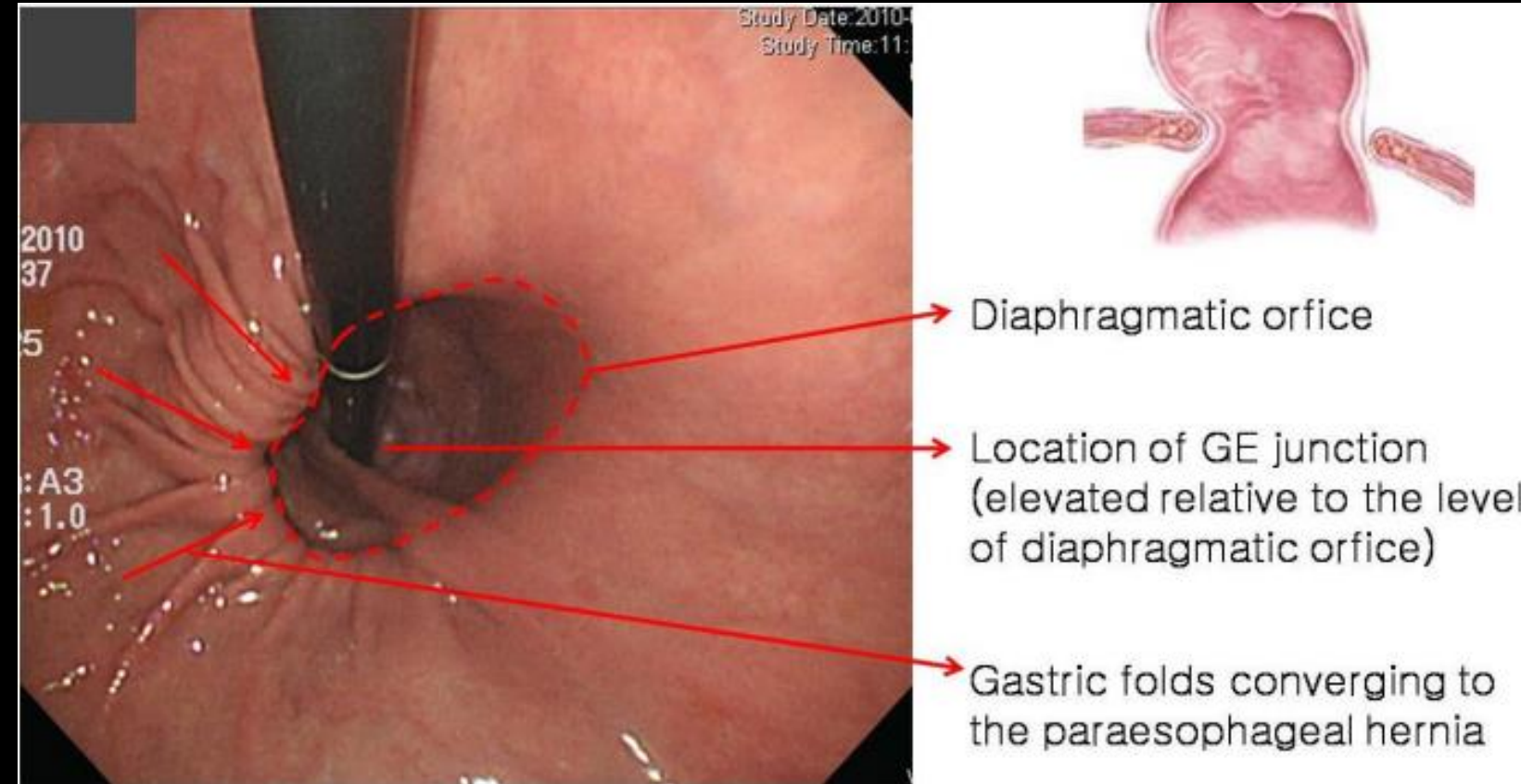


식도 열공 Hiatal hernia, type II



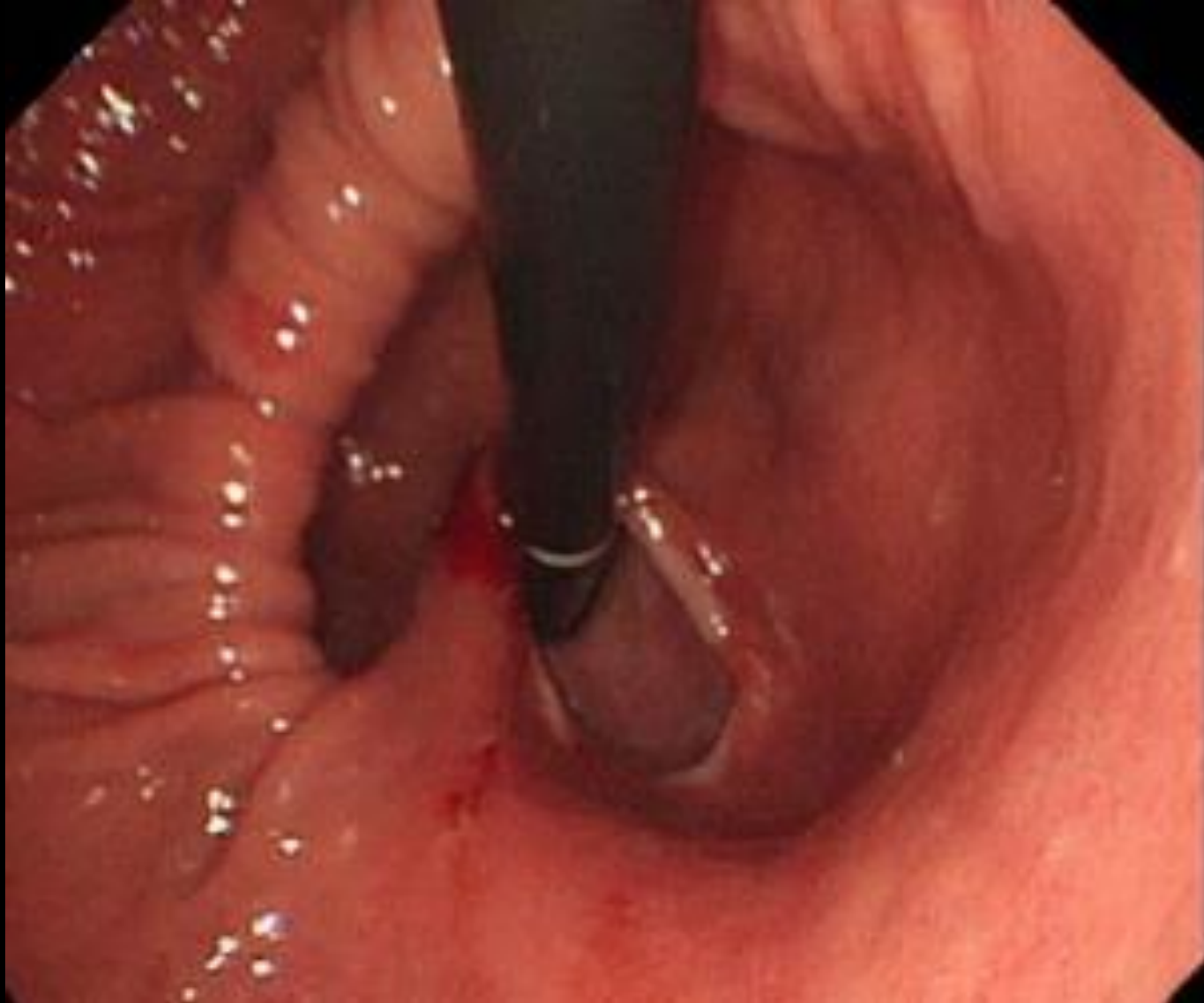
횡경막 식도인대손상은 없고
열공 자체가 늘어나서
그 틈으로 위가 흉강으로 빠져나간것

식도 열공 Hiatal hernia, type I+II

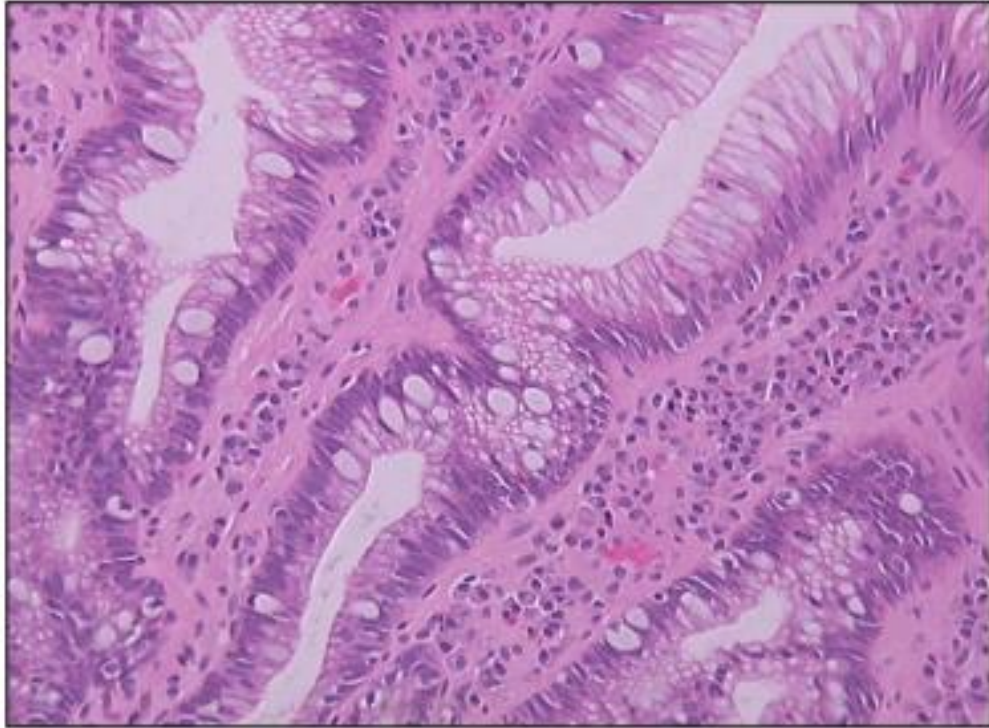
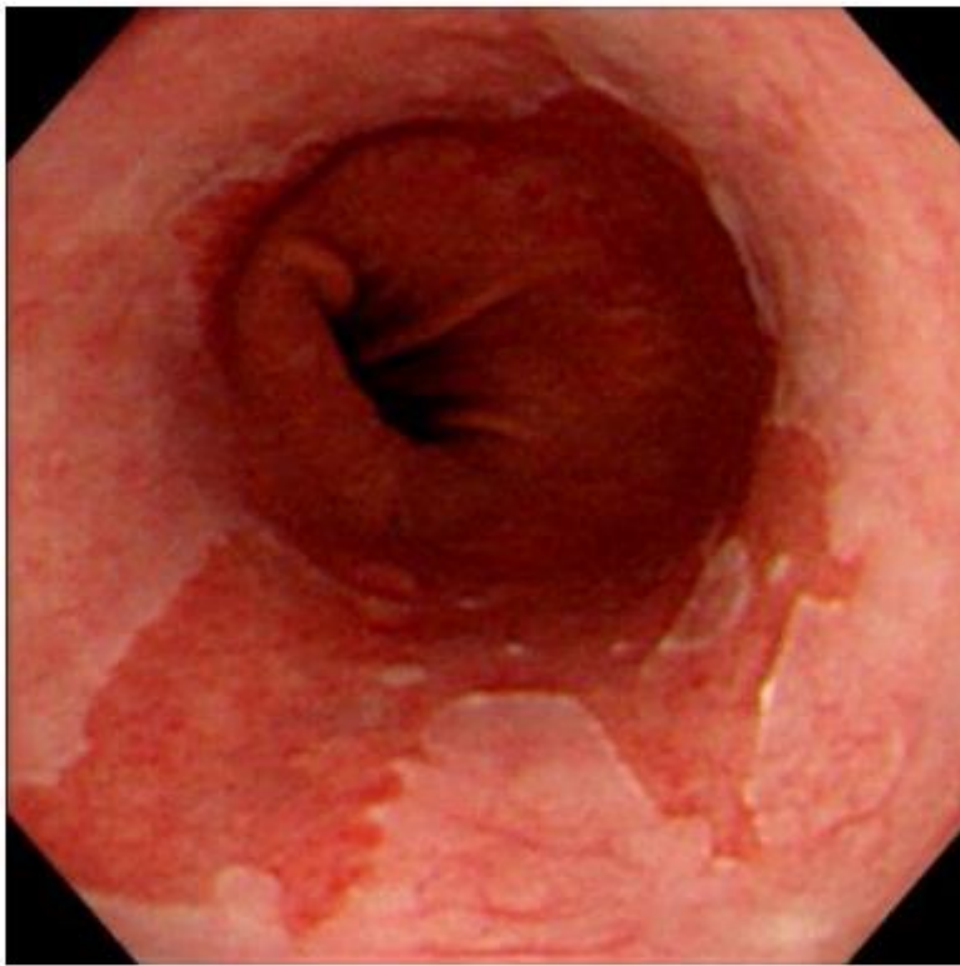


횡경막 식도인대 손상 + 식도 열공이 함께 있어 위 분문부가 흉강으로 빠져나간 형태

식도 열공 Hiatal hernia, type I+II



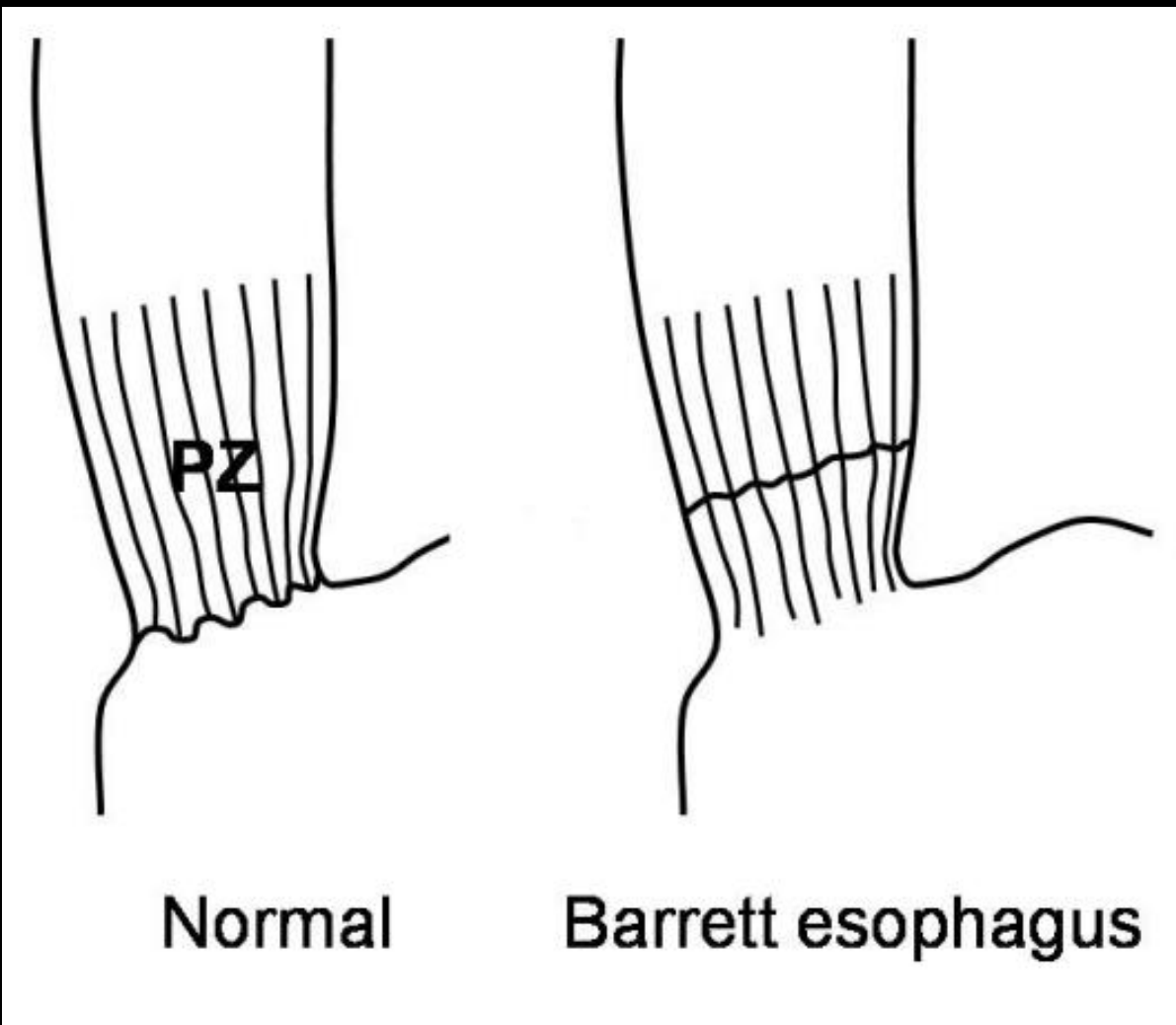
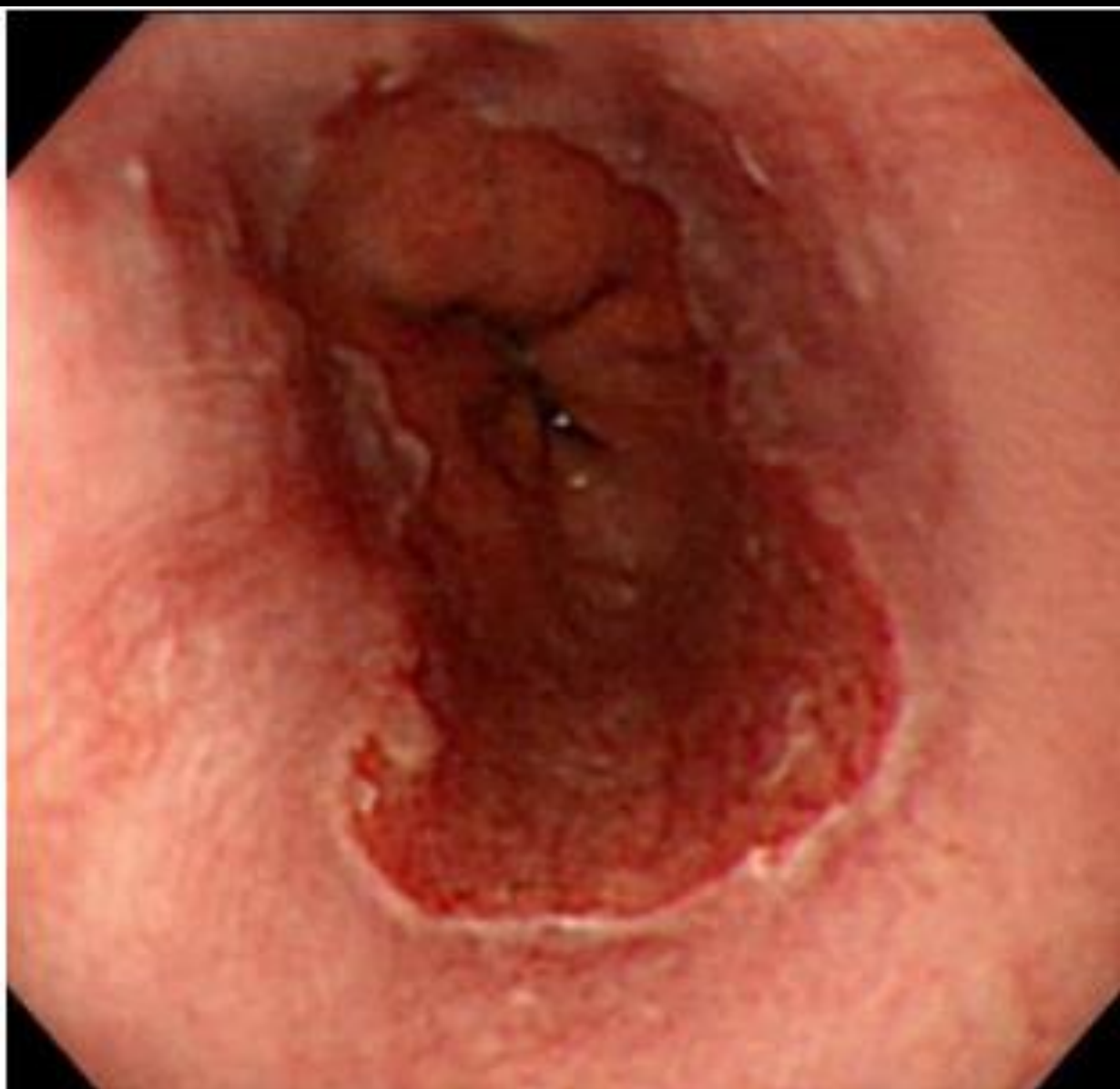
Barrett's esophagus



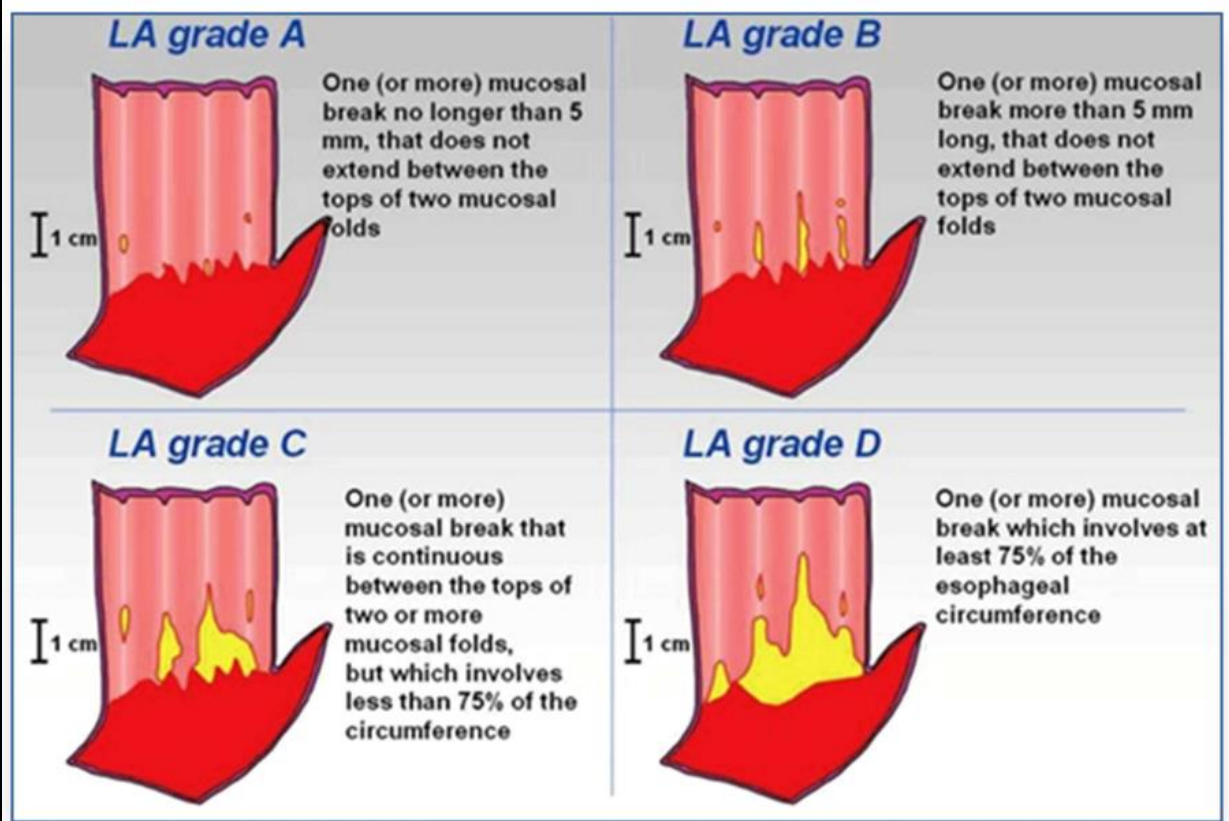
**Intestinal metaplasia
positive Goblet cells**

만성 역류로 인하여, 평편상피로 된 정상 식도 점막이 탈락되고 원주상피로 변화

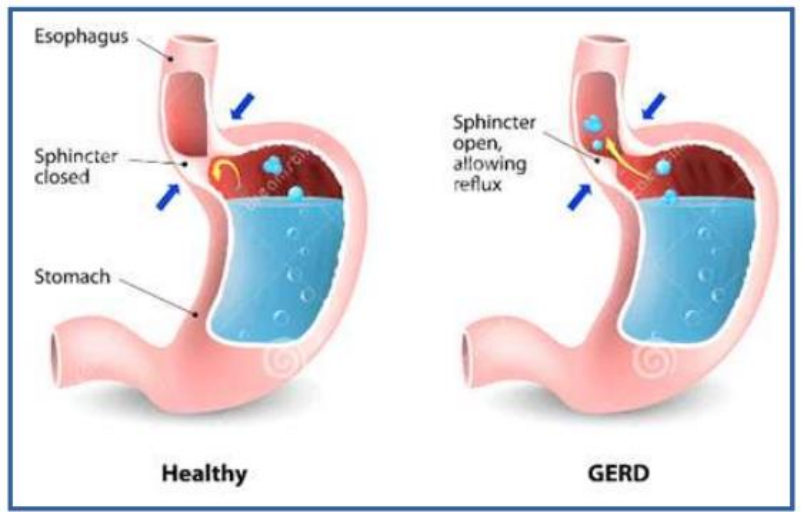
Barrett's esophagus



역류성 식도염의 분류



LA Classification of Reflux Esophagitis

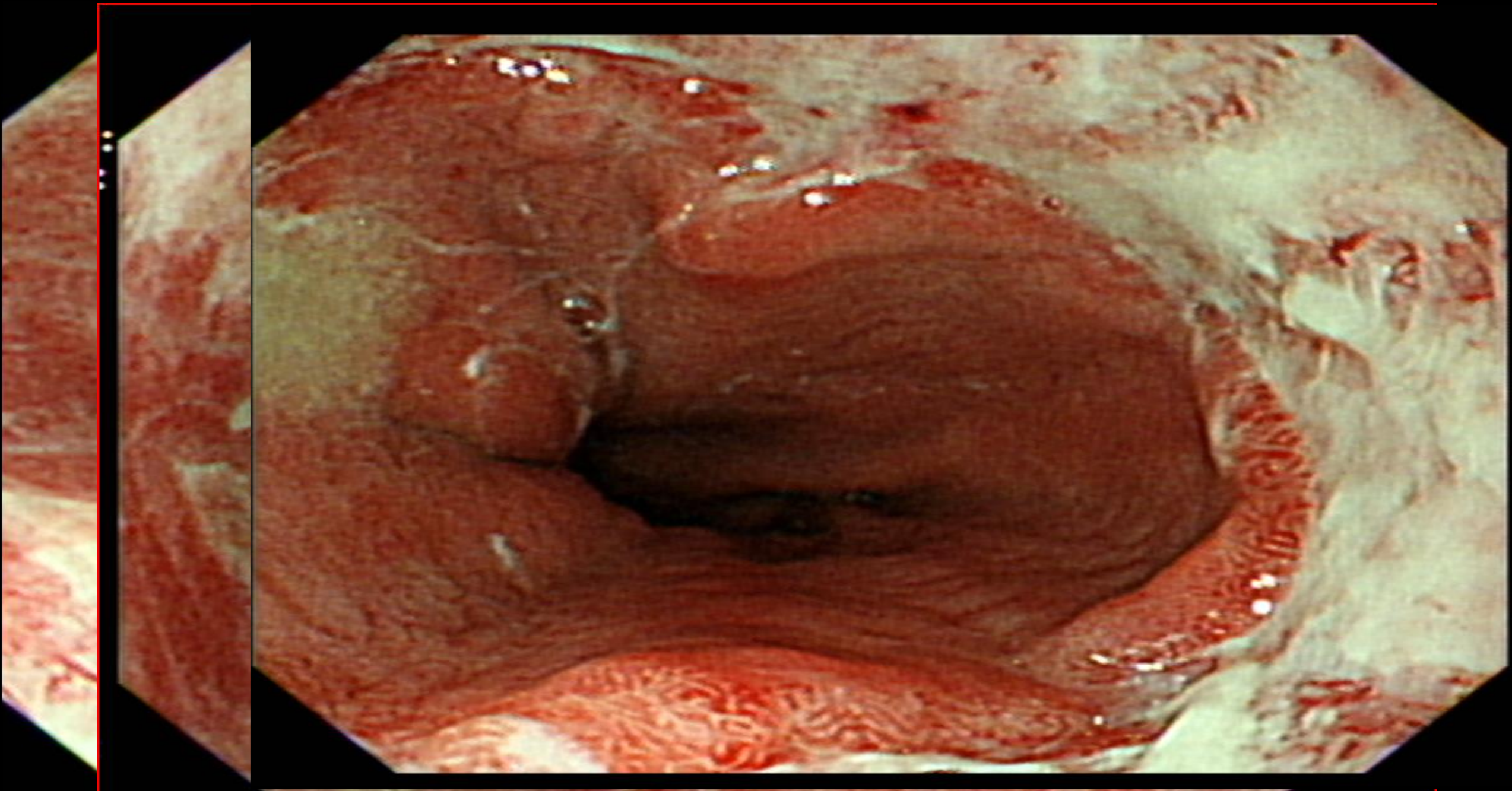


Gastroesophageal Reflux Disease

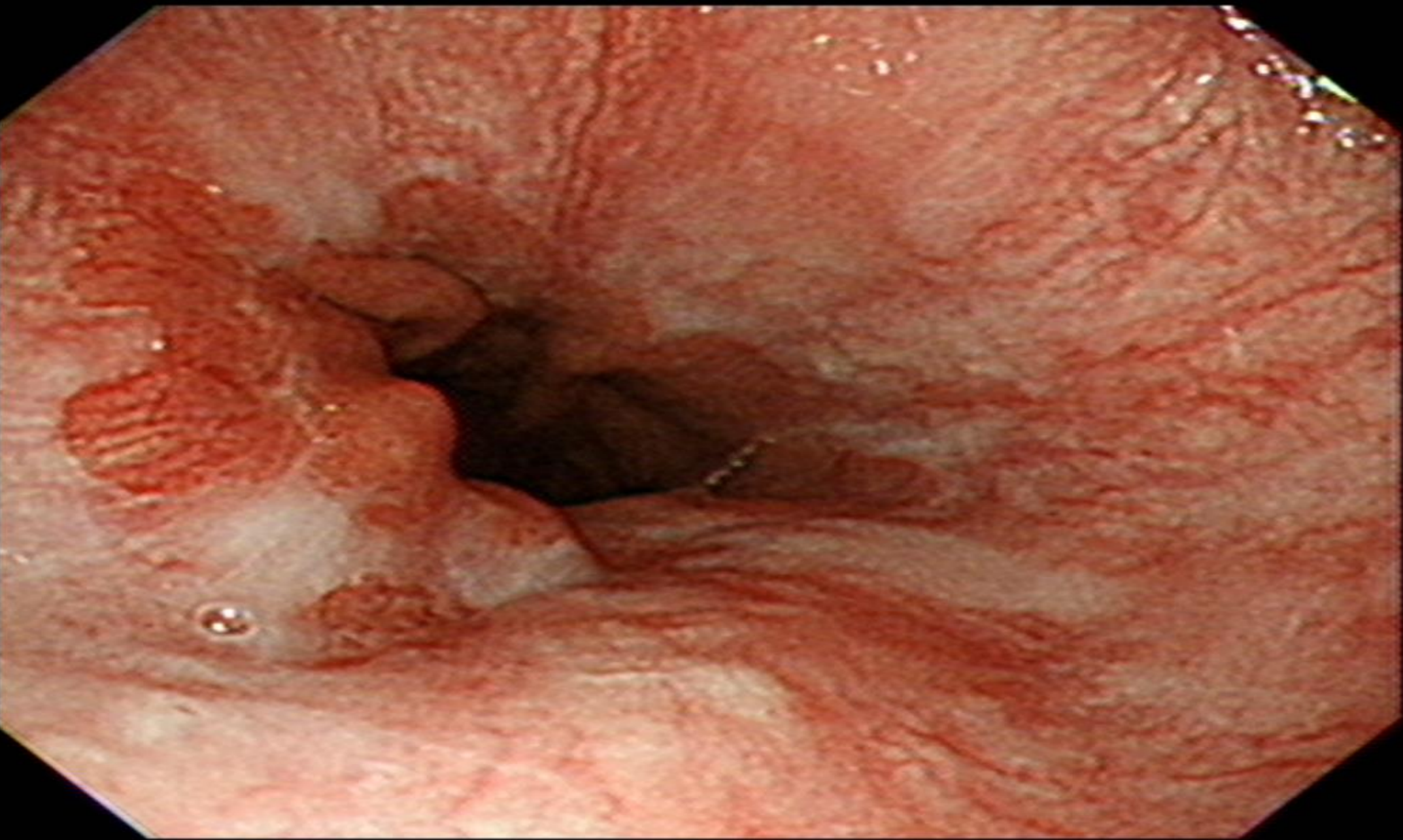

Table 2. LA classification

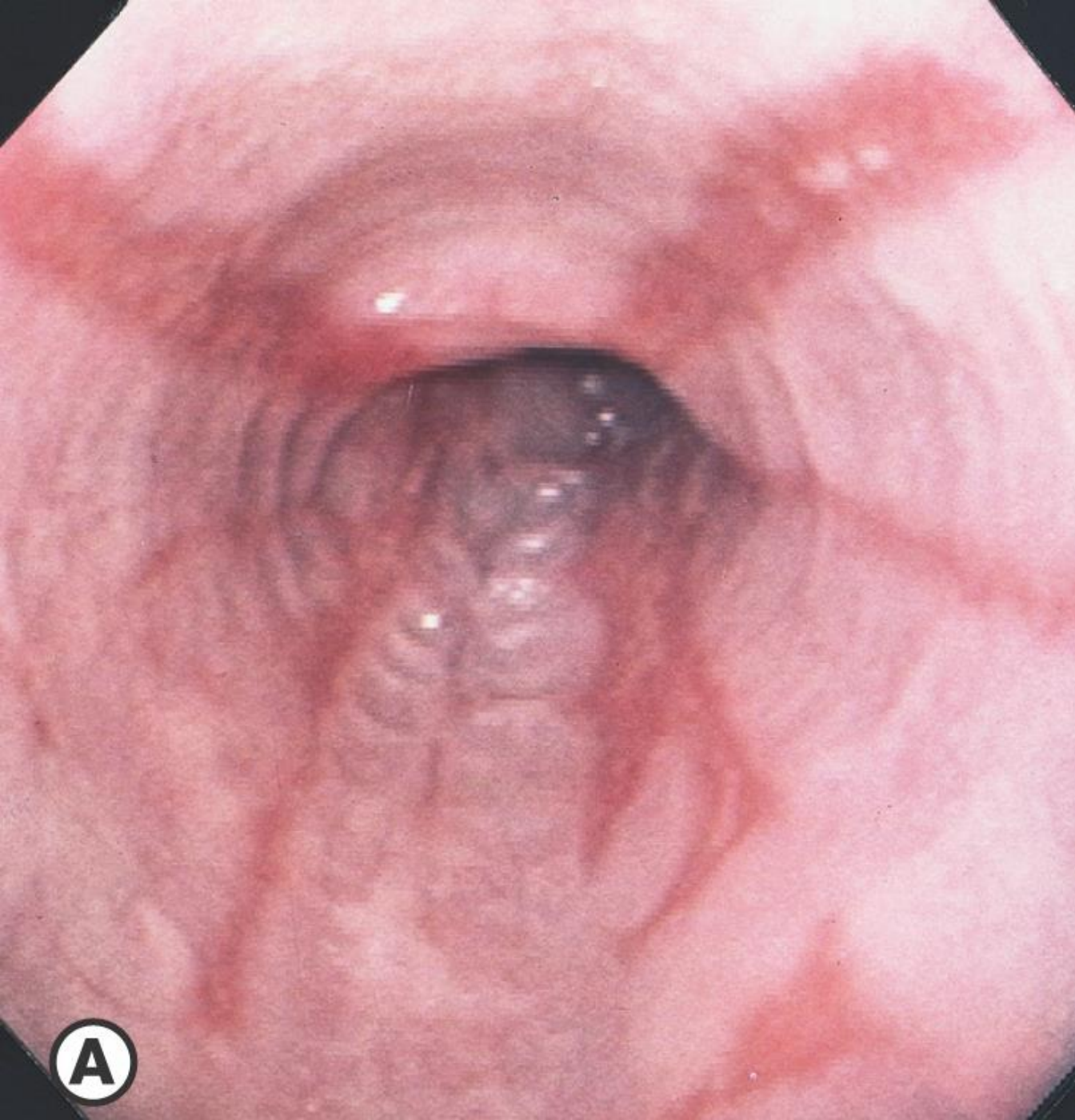
Group A	One or more mucosal breaks confined to the mucosal folds, each no longer than 5 mm
Group B	At least one mucosal break more than 5 mm long confined to the mucosal folds but not continuous between the tops of two mucosal folds
Group C	At least one mucosal break continuous between the tops of two or more mucosal folds but not circumferential
Group D	Circumferential mucosal break

역류성 식도염 LA-D



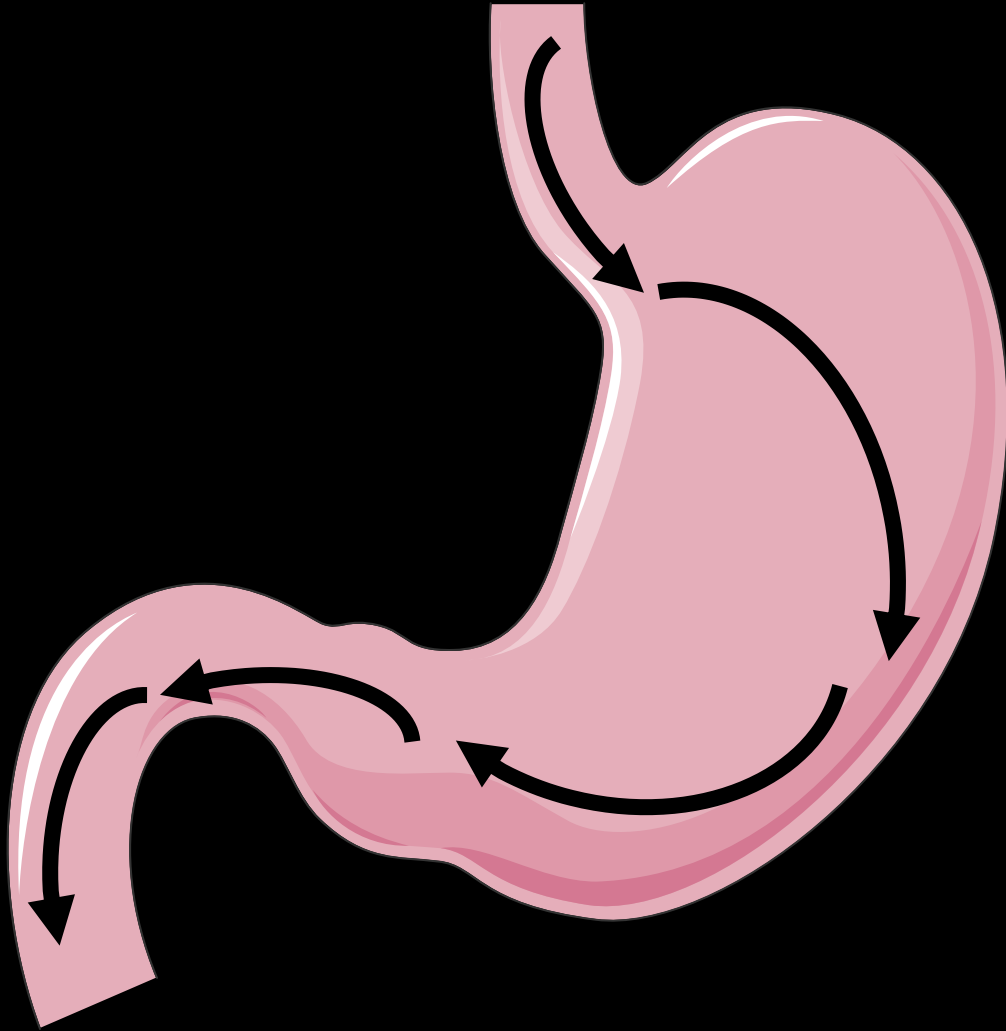
역류성 식도염 8 주 약물 치료 후, RE LA-A





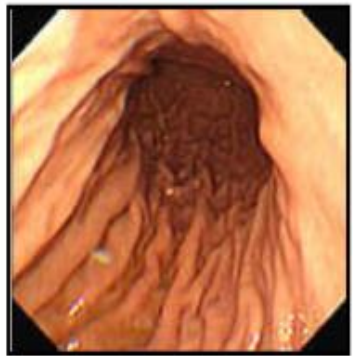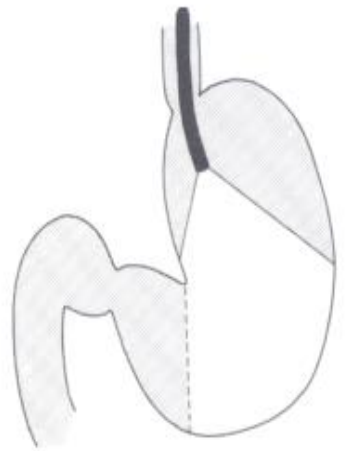
A

내시경 관찰 순서

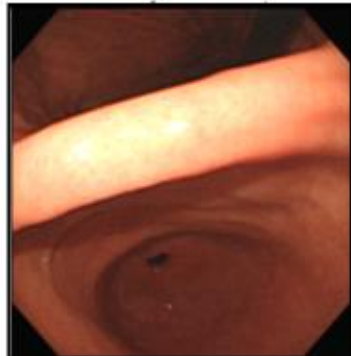
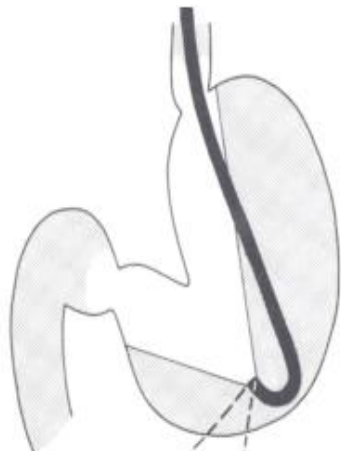


- 진입시 관찰- 후진시 관찰
- 구강 → 식도 → 십이지장 → 위 → 식도
- 십이지장
Bulb → SDA → papilla → bulb
- 위
Pylorus → antrum → angle → body → cardia
→ fundus → angle → lower body
→ upper body
- 식도
EG junction → distal → mid → upper

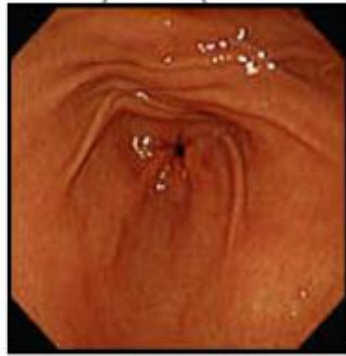
위 관찰



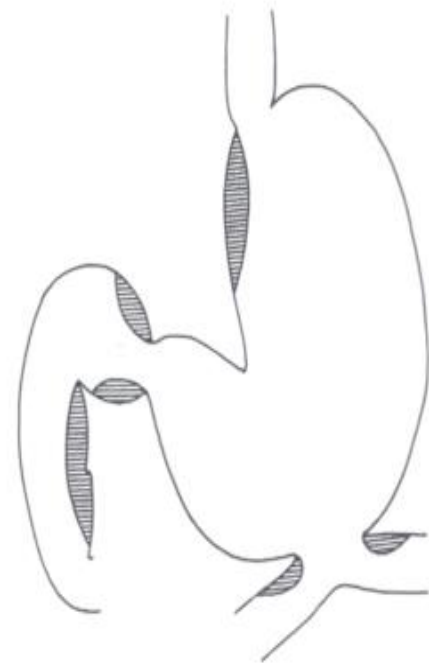
체부



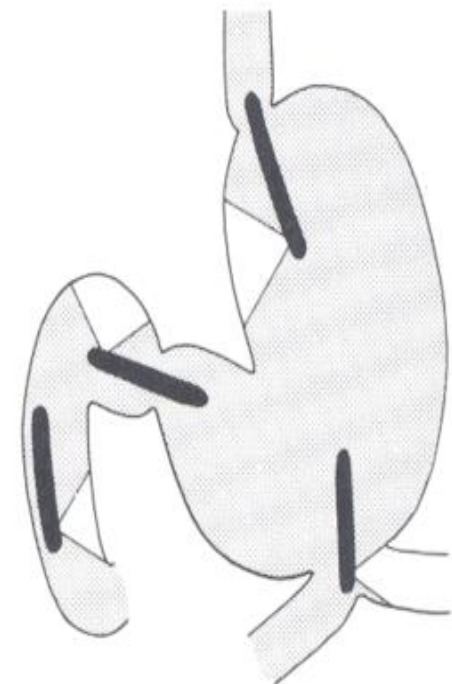
각부



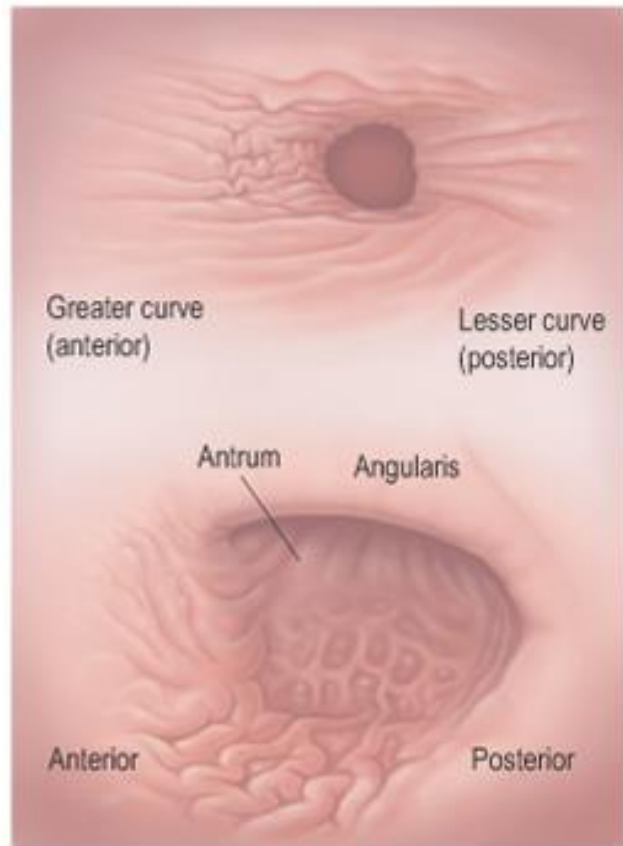
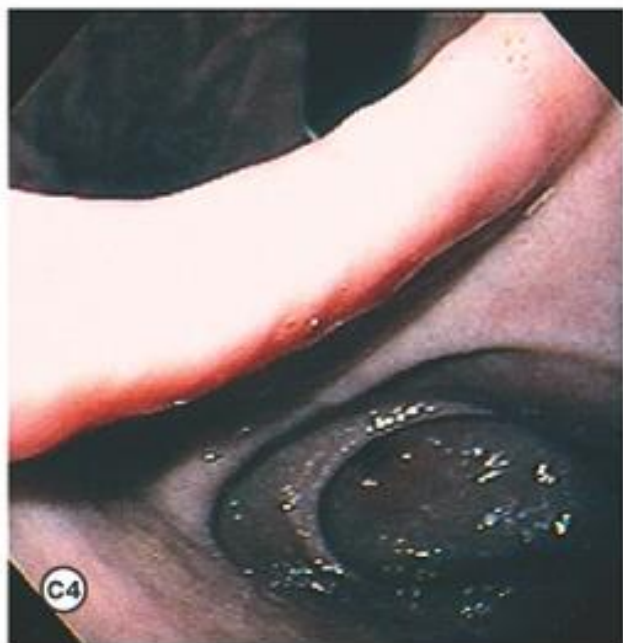
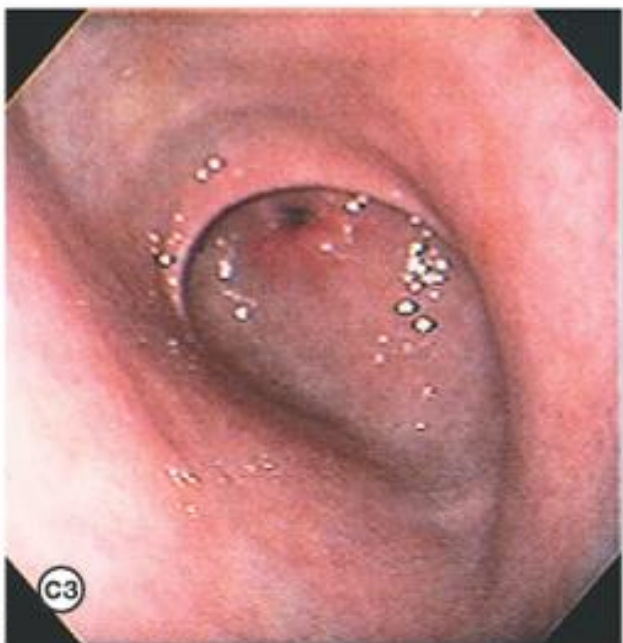
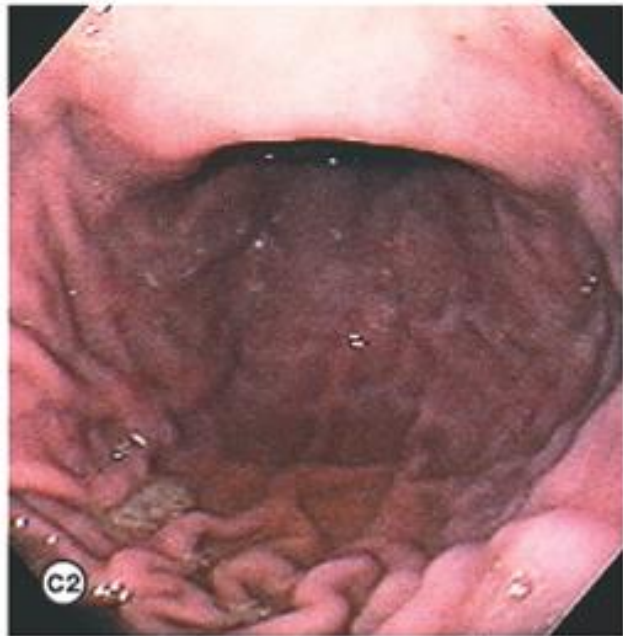
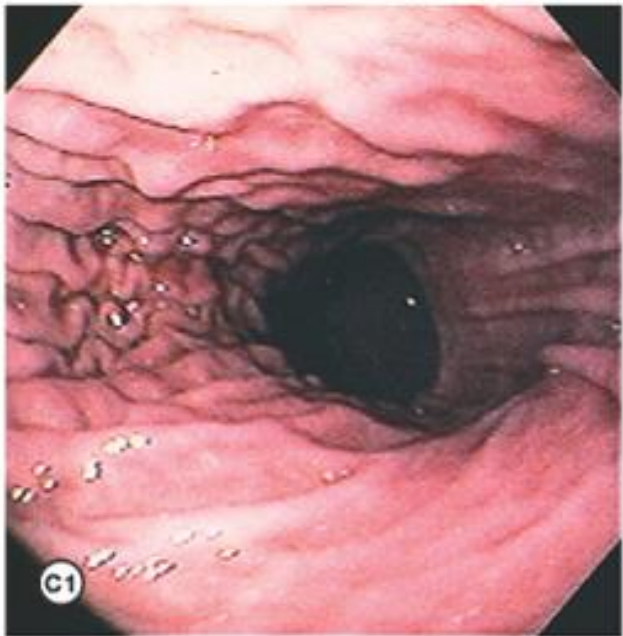
전정부

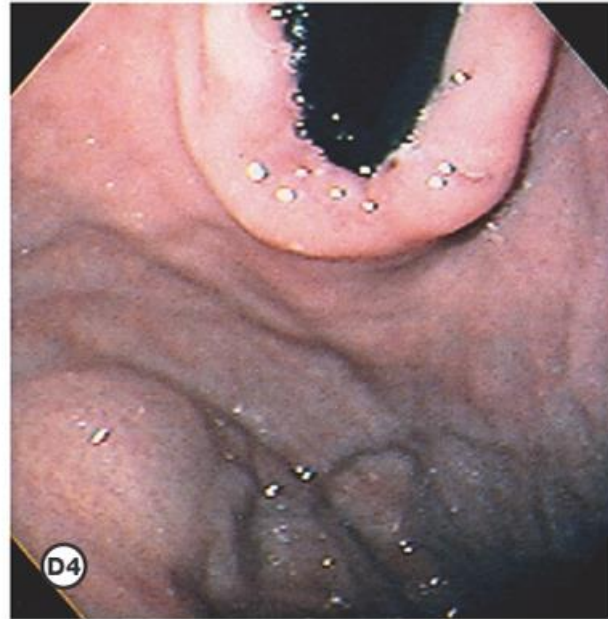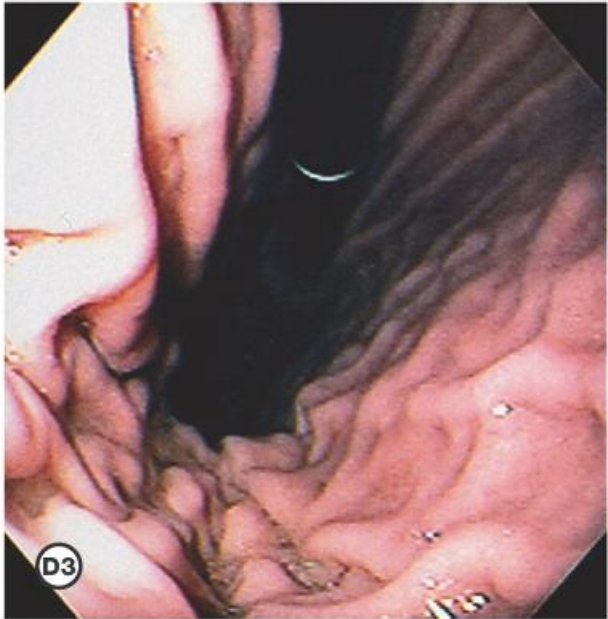
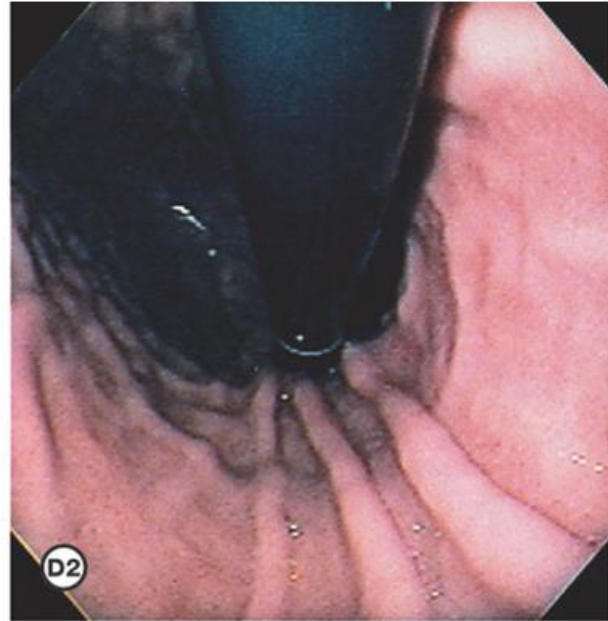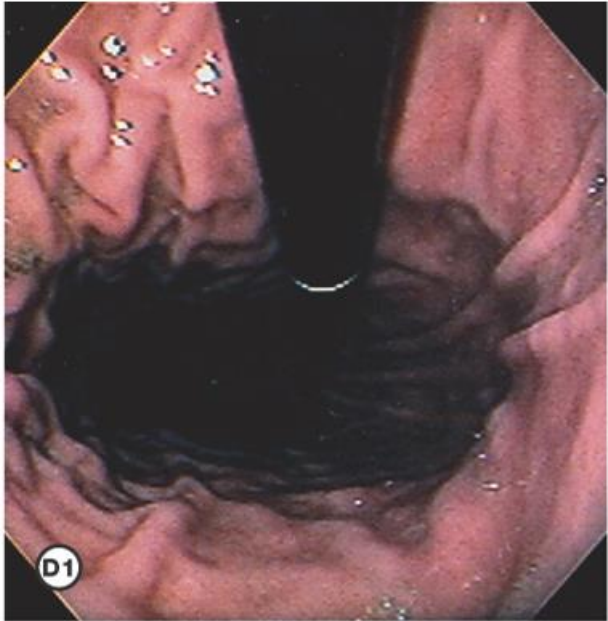


직시형내시경의 맹점

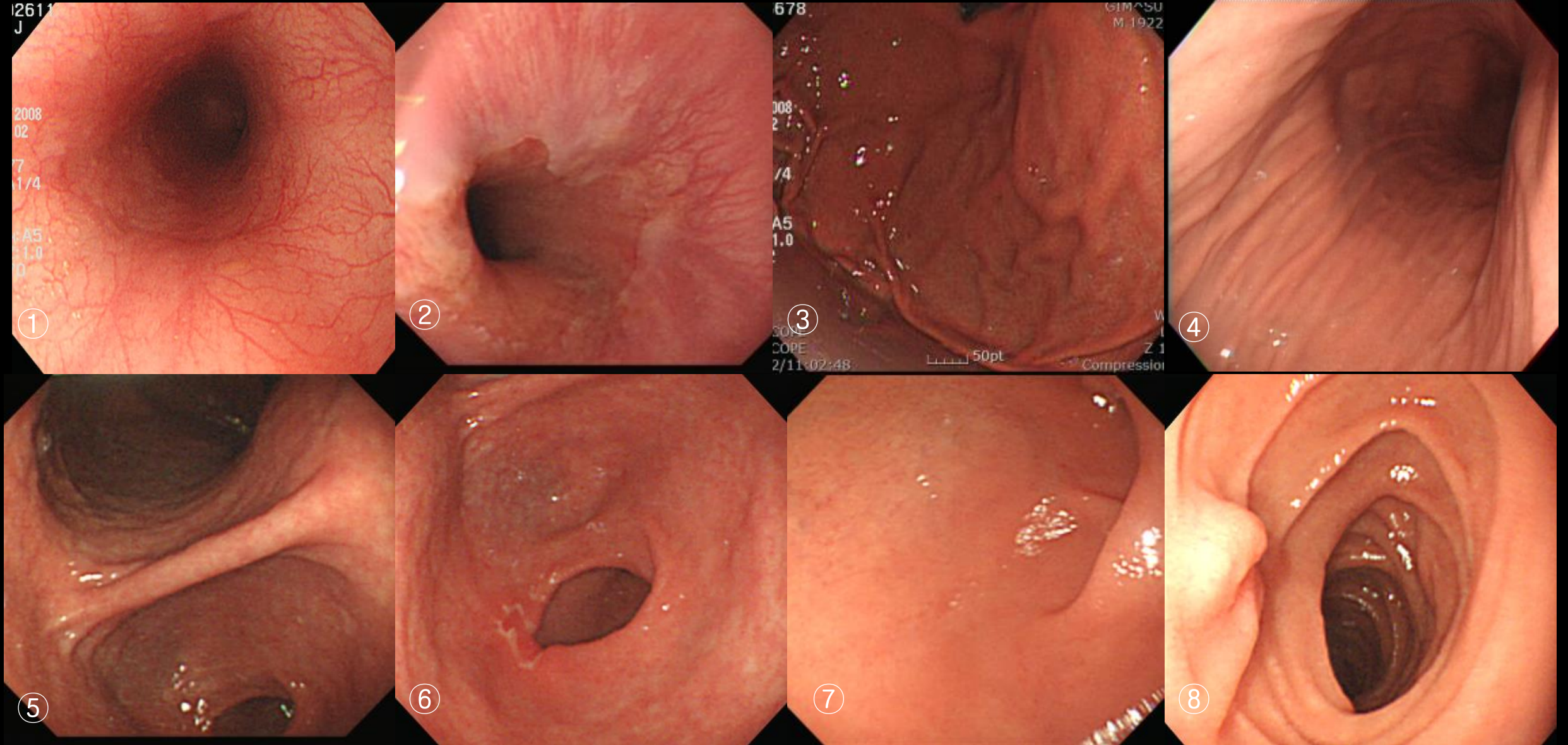


측시형이 잘보이는 부위



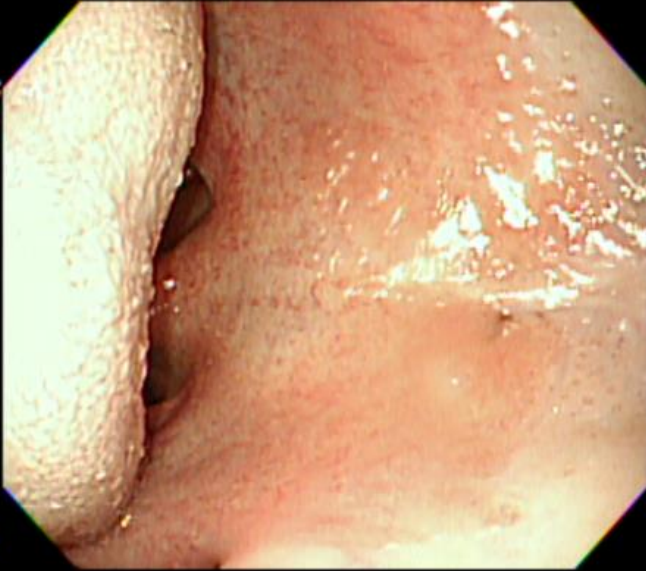


사진촬영 권장부위



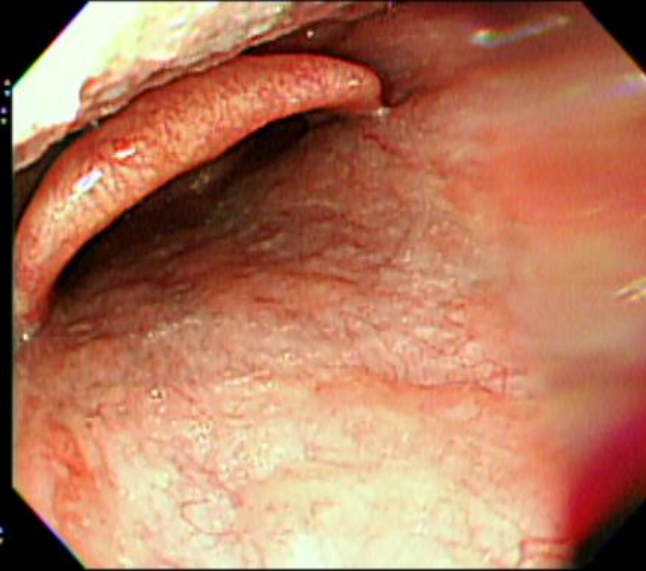
증례-랜드마크 촬영 꼼꼼히

ID No. :
Name :
Sex : Age :
D.O.Birth :
05/25/2017
12:13:31
SCV: 1
Cr: N Et: A5
Ce: 3 Z: 1.0
Physician :
Comment :

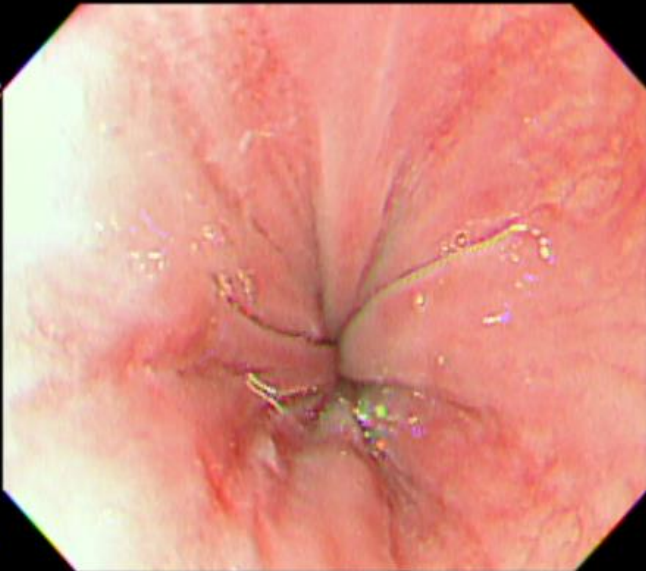


20171226
Medi.R Technology
01 (33Y)
1
2
100PT
W:256 L:128

ID No. :
Name :
Sex : Age :
D.O.Birth :
05/25/2017
12:13:36
SCV: 1
Cr: N Et: A5
Ce: 3 Z: 1.0
Physician :
Comment :

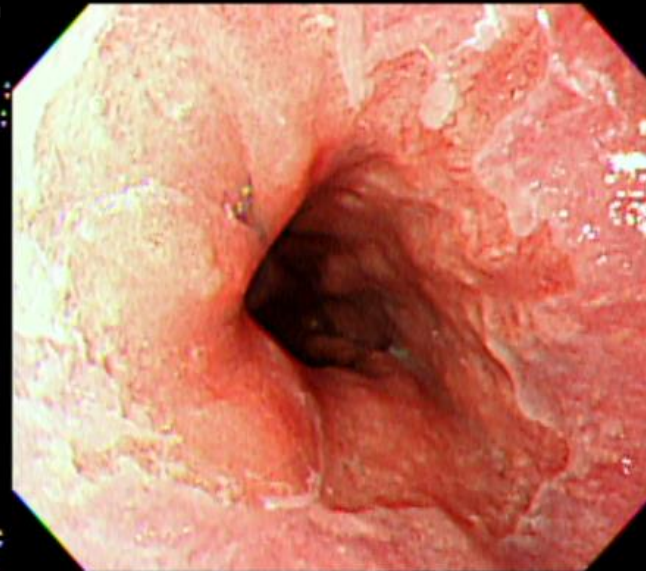


ID No. :
Name :
Sex : Age :
D.O.Birth :
05/25/2017
12:14:53
SCV: 1
Cr: N Et: A5
Ce: 3 Z: 1.0
Physician :
Comment :



20171226
Medi.R Technology
01 (33Y)
17
1
100PT

ID No. :
Name :
Sex : Age :
D.O.Birth :
05/25/2017
12:15:02
SCV: 1
Cr: N Et: A5
Ce: 3 Z: 1.0
Physician :
Comment :



증례-병변부위를 잘 촬영

ID No. :
Name :

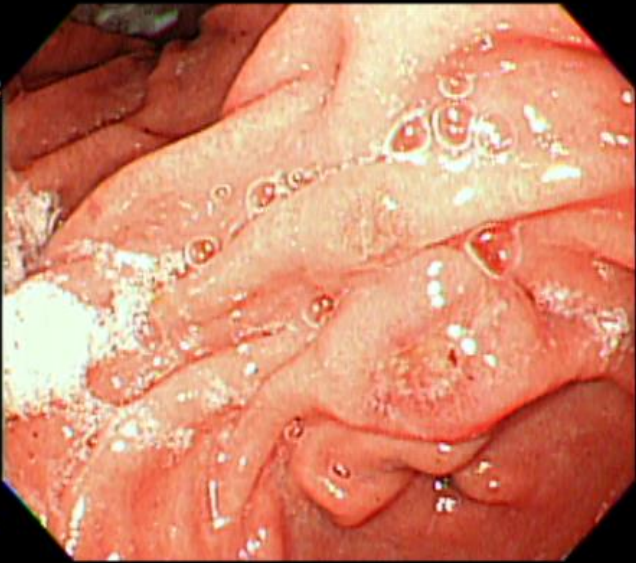
Sex : Age :
D.O.Birth :

05/25/2017
12: 15: 13

SCV: 1

Cr: N Et: A5
Ce: 3 Z: 1.0

Physician :
Comment :



medi.R technology

M
25Y

100PT

W:266 L:128

ID No. :
Name :

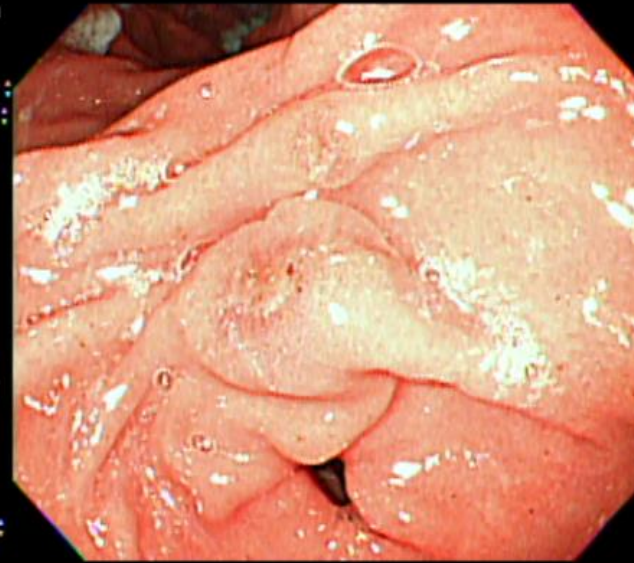
Sex : Age :
D.O.Birth :

05/25/2017
12: 15: 19

SCV: 1

Cr: N Et: A5
Ce: 3 Z: 1.0

Physician :
Comment :



ID No. :
Name :

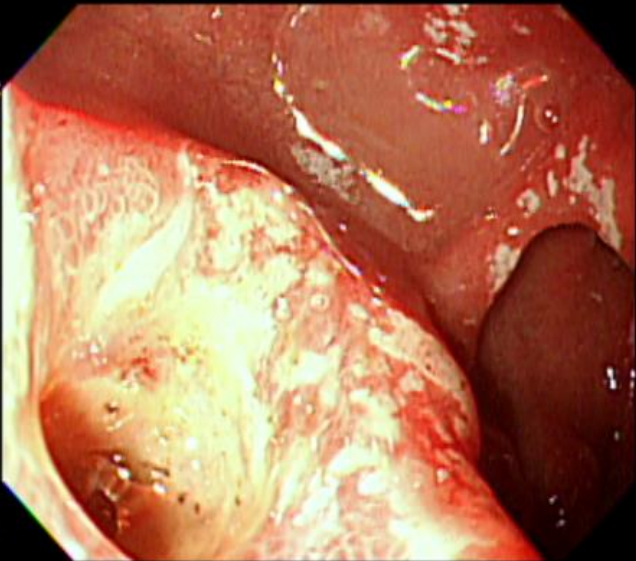
Sex : Age :
D.O.Birth :

05/25/2017
12: 15: 26

SCV: 1

Cr: N Et: A5
Ce: 3 Z: 1.0

Physician :
Comment :



medi.R Techno

M
25Y

100PT

ID No. :
Name :

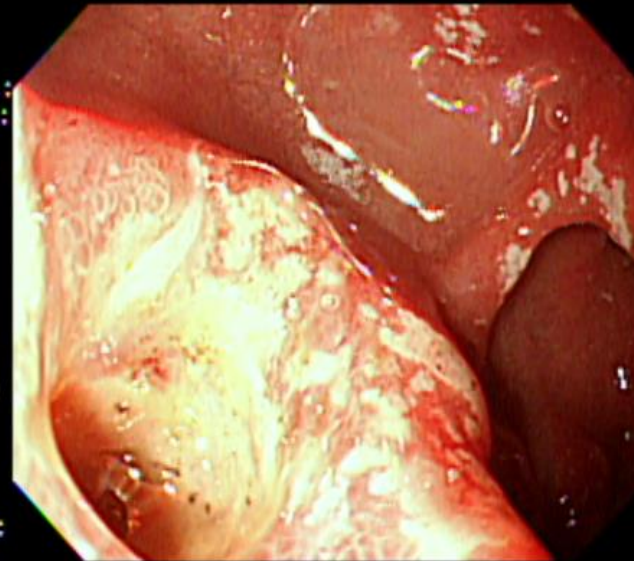
Sex : Age :
D.O.Birth :

05/25/2017
12: 15: 26

SCV: 1

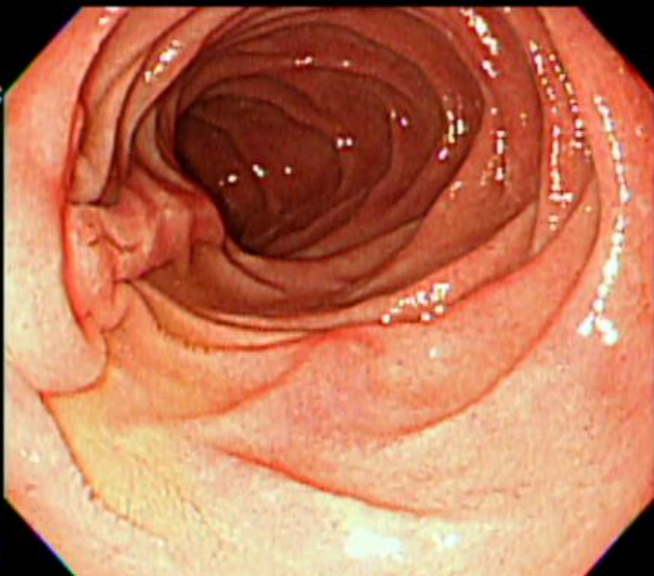
Cr: N Et: A5
Ce: 3 Z: 1.0

Physician :
Comment :



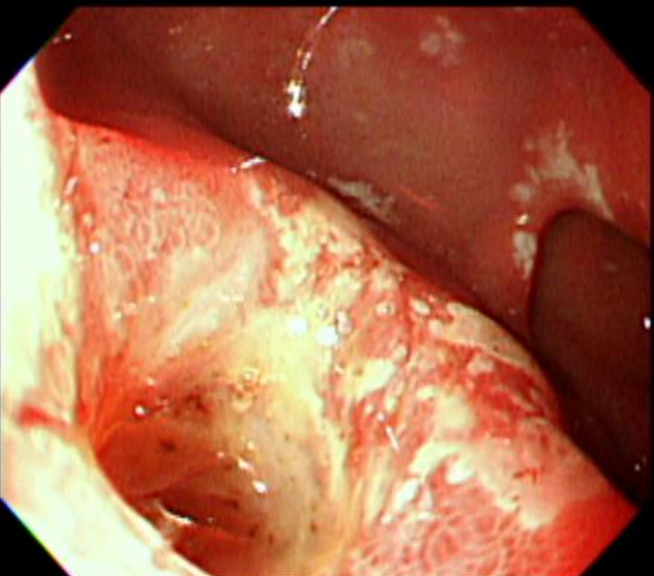
증례 - Duodenal deep ulcer with perfo

ID No. : ■
 Name :
 Sex : Age :
 D.O.Birth :
 05/25/2017
 12:15:34
 SCV: 1
 Cr: N Et: A5
 Ce: 3 Z: 1.0
 Physician :
 Comment :
 W:256 L:128



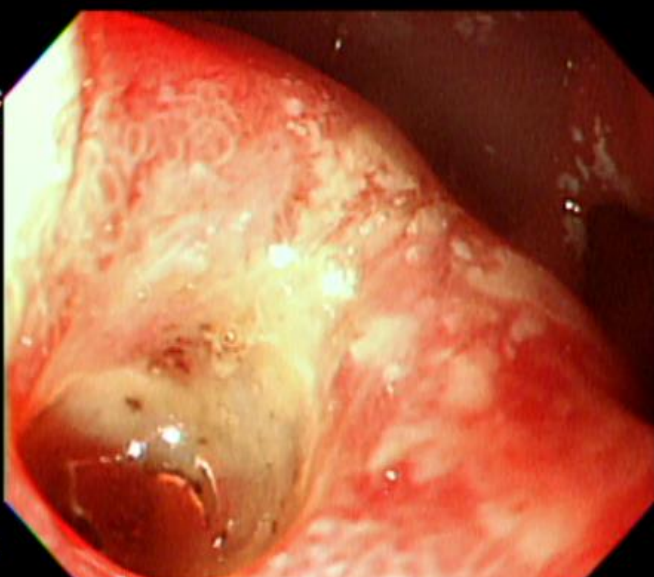
Medi.R Technology

ID No. : ■
 Name :
 Sex : Age :
 D.O.Birth :
 05/25/2017
 12:15:43
 SCV: 1
 Cr: N Et: A5
 Ce: 3 Z: 1.0
 Physician :
 Comment :



Medi.R Technology

ID No. : ■
 Name :
 Sex : Age :
 D.O.Birth :
 05/25/2017
 12:16:00
 SCV: 1
 Cr: N Et: A5
 Ce: 3 Z: 1.0
 Physician :
 Comment :



Medi.R Technology

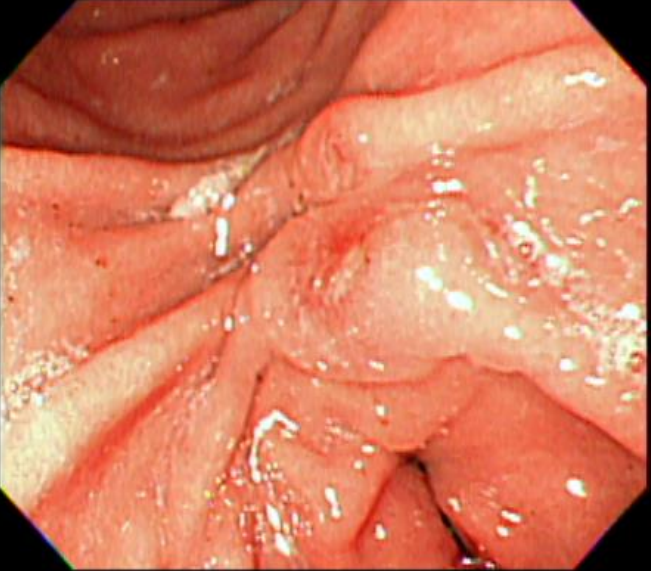
ID No. : ■
 Name :
 Sex : Age :
 D.O.Birth :
 05/25/2017
 12:16:07
 SCV: 1
 Cr: N Et: A5
 Ce: 3 Z: 1.0
 Physician :
 Comment :



Medi.R Technology

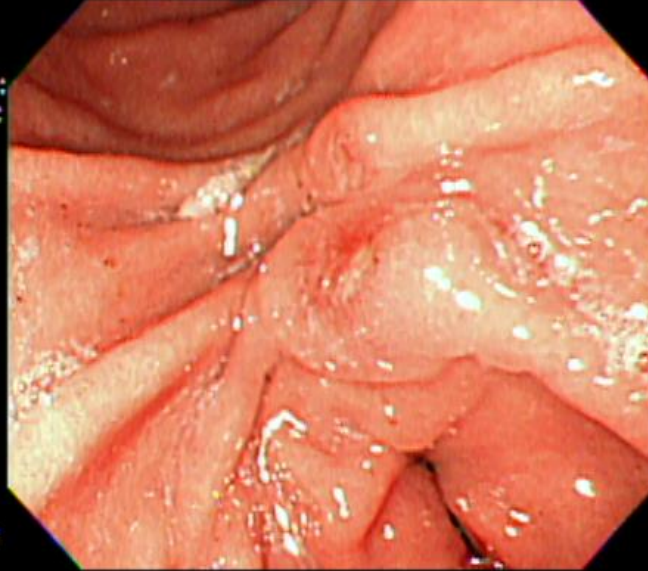
증례 - DU, GU → Hp infection

ID No. :
Name :
Sex : Age :
D.O.Birth :
05/25/2017
12:16:14
SCV:1
Cr: N Et: A5
Ce: 3 Z: 1.0
Physician :
Comment :

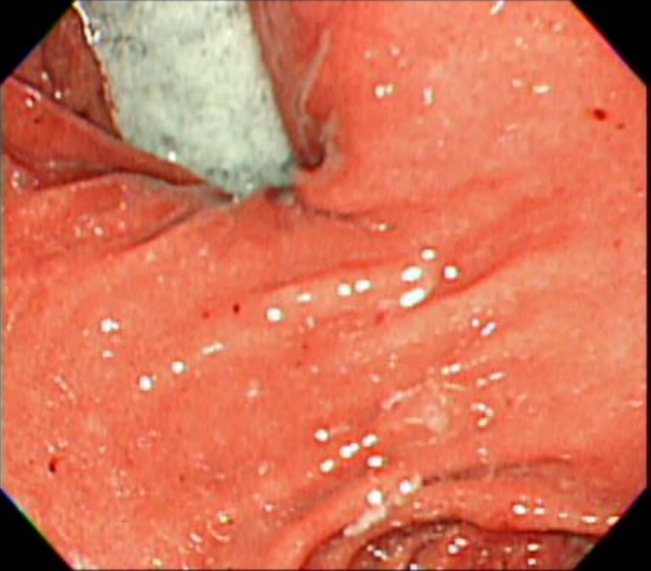


Medi.R Technology
25Y
100PT
W:256 L:128

ID No. :
Name :
Sex : Age :
D.O.Birth :
05/25/2017
12:16:14
SCV:1
Cr: N Et: A5
Ce: 3 Z: 1.0
Physician :
Comment :

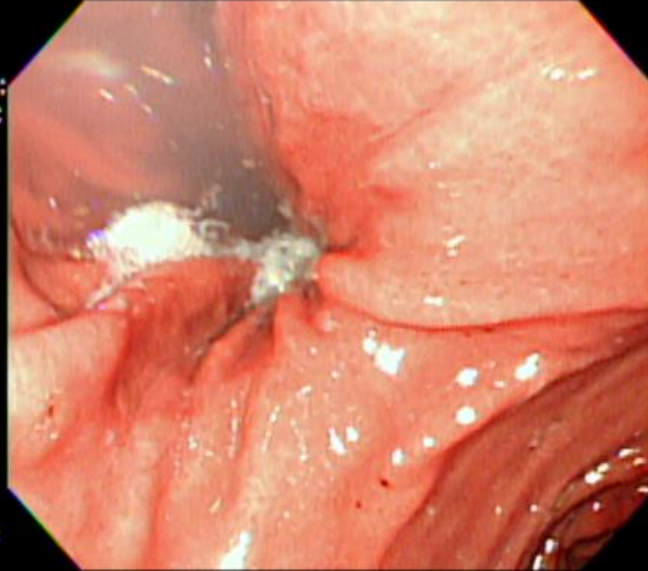


ID No. :
Name :
Sex : Age :
D.O.Birth :
05/25/2017
12:16:16
SCV:1
Cr: N Et: A5
Ce: 3 Z: 1.0
Physician :
Comment :



20171226
Medi.R Technology
25Y
100PT

ID No. :
Name :
Sex : Age :
D.O.Birth :
05/25/2017
12:16:24
SCV:1
Cr: N Et: A5
Ce: 3 Z: 1.0
Physician :
Comment :



증례- 병변 없는 부위도 빠르게 스캔

ID No. : 20171226
 Name : 501 (83Y)
 Sex : Age :
 D.O.Birth : 05/25/2017 12:17:02
 SCV: 1
 Cr: N Bc: A5
 Cc: 3 Z: 1.0
 Physician :
 Comment :



W:258 L:128

ID No. : 20171226
 Name : 501 (83Y)
 Sex : Age :
 D.O.Birth : 05/25/2017 12:17:18
 SCV: 1
 Cr: N Bc: A5
 Cc: 3 Z: 1.0
 Physician :
 Comment :



W:256 L:128

ID No. : 20171226
 Name : 501 (83Y)
 Sex : Age :
 D.O.Birth : 05/25/2017 12:17:31
 SCV: 1
 Cr: N Bc: A5
 Cc: 3 Z: 1.0
 Physician :
 Comment :



W:256 L:128

ID No. : 20171226
 Name : 501 (83Y)
 Sex : Age :
 D.O.Birth : 05/25/2017 12:17:33
 SCV: 1
 Cr: N Bc: A5
 Cc: 3 Z: 1.0
 Physician :
 Comment :



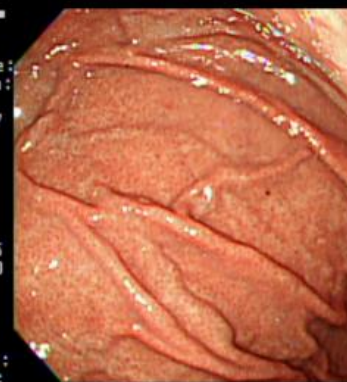
W:258 L:128

ID No. : 20171226
 Name : 501 (83Y)
 Sex : Age :
 D.O.Birth : 05/25/2017 12:17:36
 SCV: 1
 Cr: N Bc: A5
 Cc: 3 Z: 1.0
 Physician :
 Comment :




W:256 L:128

ID No. : 20171226
 Name : 501 (83Y)
 Sex : Age :
 D.O.Birth : 05/25/2017 12:17:40
 SCV: 1
 Cr: N Bc: A5
 Cc: 3 Z: 1.0
 Physician :
 Comment :



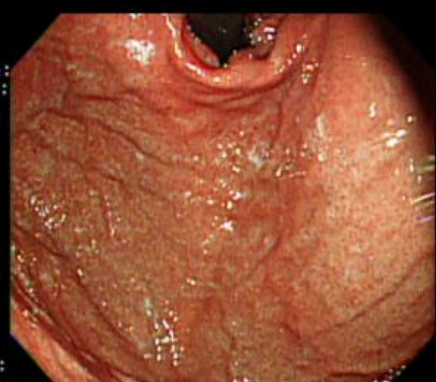
W:256 L:128

ID No. : 20171226
 Name : 501 (83Y)
 Sex : Age :
 D.O.Birth : 05/25/2017 12:17:42
 SCV: 1
 Cr: N Bc: A5
 Cc: 3 Z: 1.0
 Physician :
 Comment :



W:258 L:128

ID No. : 20171226
 Name : 501 (83Y)
 Sex : Age :
 D.O.Birth : 05/25/2017 12:17:44
 SCV: 1
 Cr: N Bc: A5
 Cc: 3 Z: 1.0
 Physician :
 Comment :



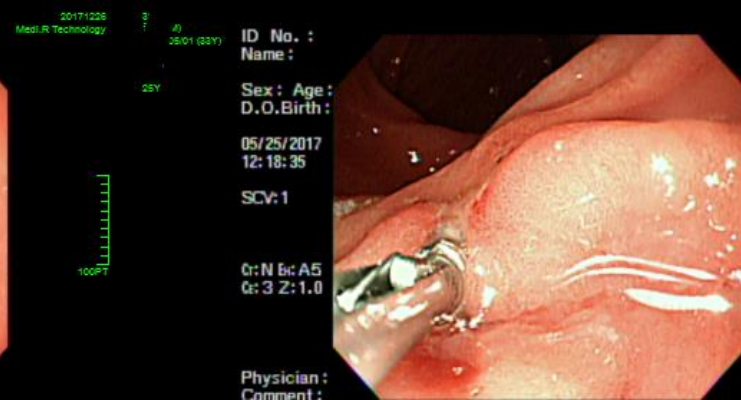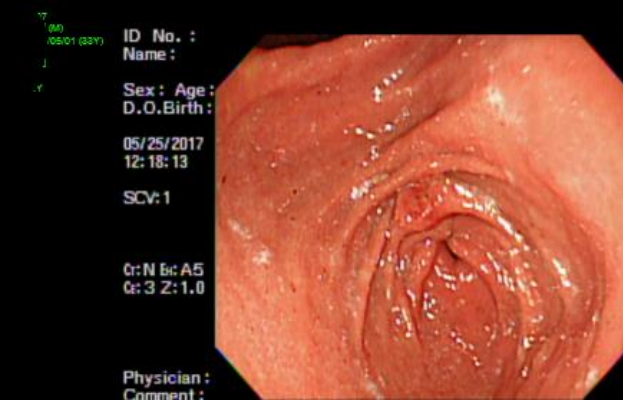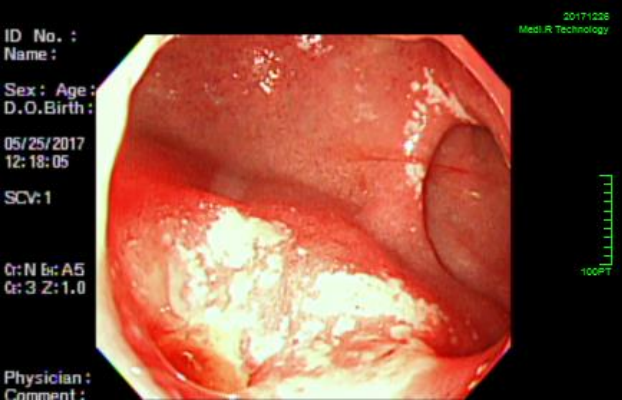
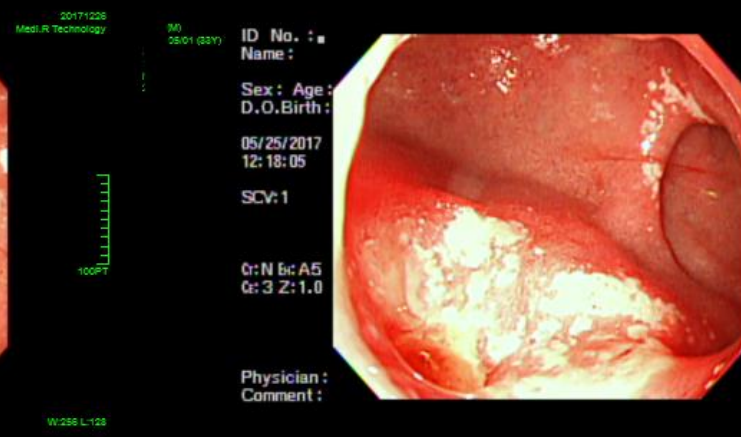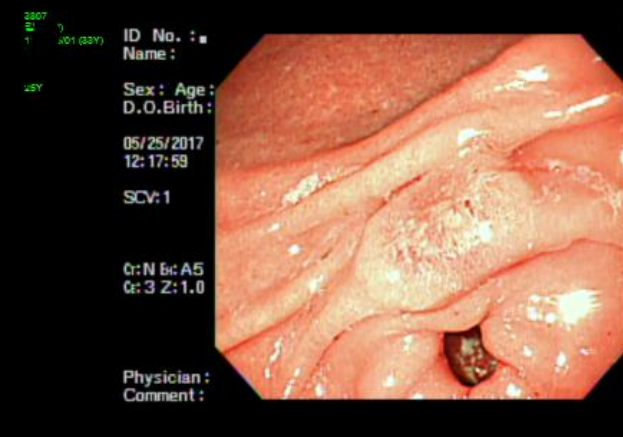
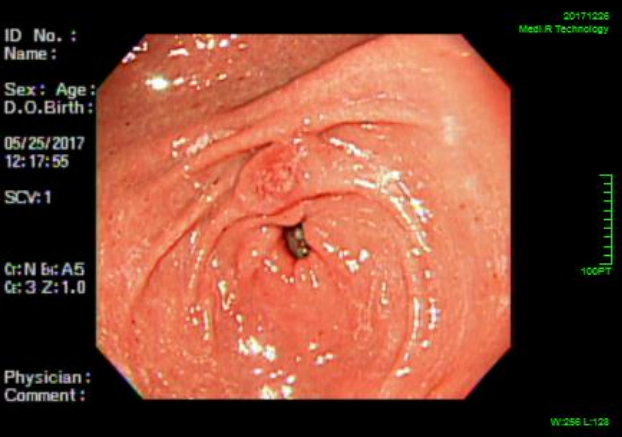
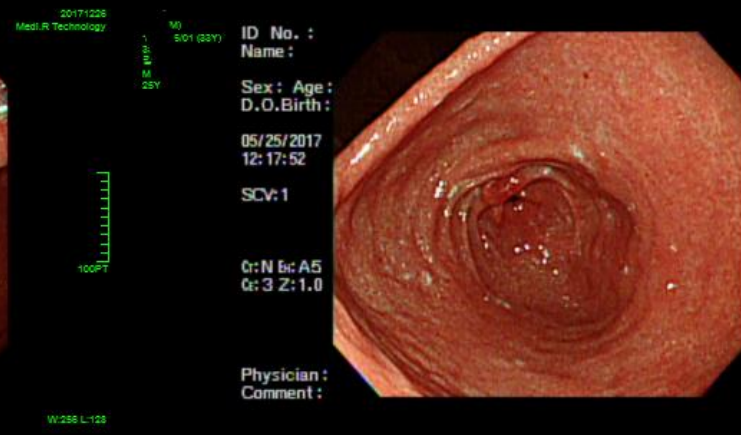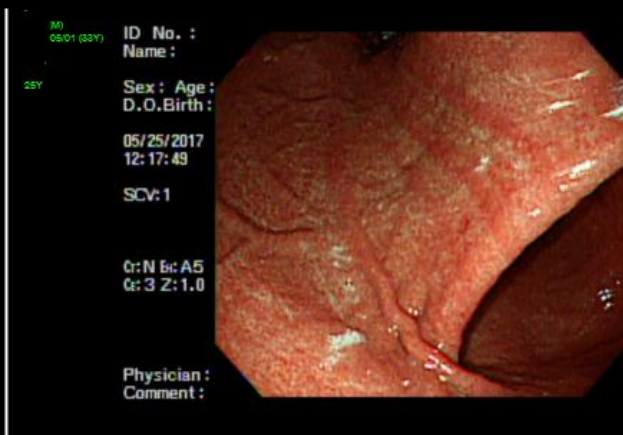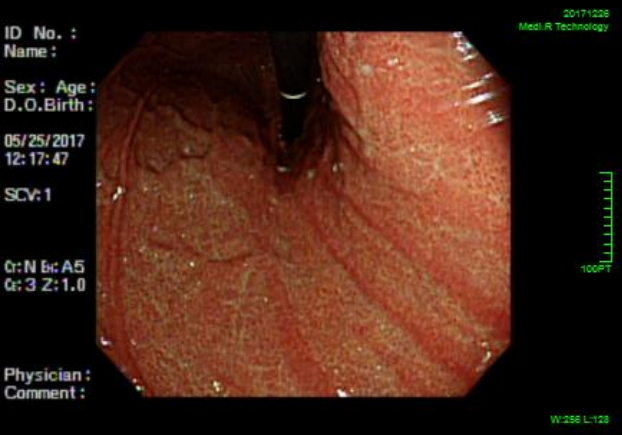
W:256 L:128

ID No. : 20171226
 Name : 501 (83Y)
 Sex : Age :
 D.O.Birth : 05/25/2017 12:17:46
 SCV: 1
 Cr: N Bc: A5
 Cc: 3 Z: 1.0
 Physician :
 Comment :



W:256 L:128

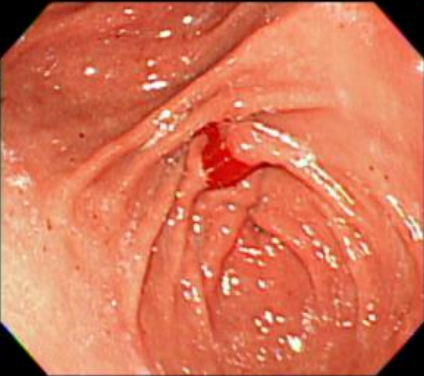
증례- 조직 검사 시 사진촬영



증례- 조직 검사 후 기록

20171228
Medi.R Technology

ID No. :
Name :
Sex : Age :
D.O.Birth :
05/25/2017
12:18:47
SCV:1
Cr:N Bc:A5
C:3 Z:1.0

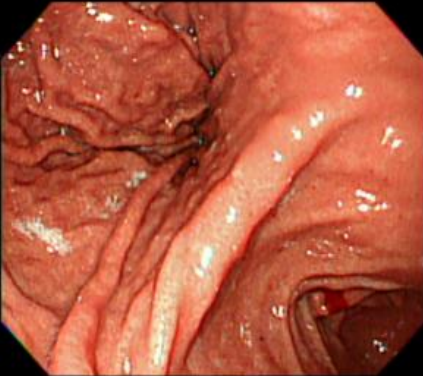


Physician :
Comment :

W:256 L:128

20171228
Medi.R Technology

ID No. :
Name :
Sex : Age :
D.O.Birth :
05/25/2017
12:18:53
SCV:1
Cr:N Bc:A5
C:3 Z:1.0



Physician :
Comment :

W:256 L:128

20171228
Medi.R Technology

ID No. :
Name :
Sex : Age :
D.O.Birth :
05/25/2017
12:19:01
SCV:1
Cr:N Bc:A5
C:3 Z:1.0




Physician :
Comment :

W:256 L:128

20171228
Medi.R Technology

ID No. :
Name :
Sex : Age :
D.O.Birth :
05/25/2017
12:19:06
SCV:1
Cr:N Bc:A5
C:3 Z:1.0



Physician :
Comment :

W:256 L:128

20171228
Medi.R Technology

ID No. :
Name :
Sex : Age :
D.O.Birth :
05/25/2017
12:19:09
SCV:1
Cr:N Bc:A5
C:3 Z:1.0



Physician :
Comment :

W:256 L:128

20171228
Medi.R Technology

ID No. :
Name :
Sex : Age :
D.O.Birth :
05/25/2017
12:19:30
SCV:1
Cr:N Bc:A5
C:3 Z:1.0

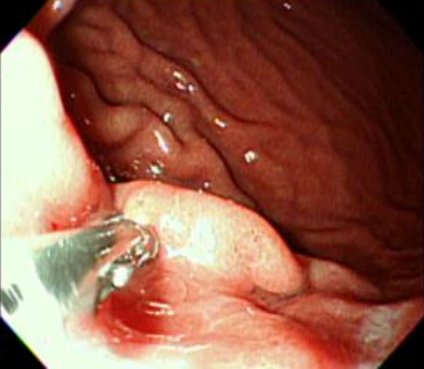


Physician :
Comment :

W:256 L:128

20171228
Medi.R Technology

ID No. :
Name :
Sex : Age :
D.O.Birth :
05/25/2017
12:19:39
SCV:1
Cr:N Bc:A5
C:3 Z:1.0



Physician :
Comment :

W:256 L:128

20171228
Medi.R Technology

ID No. :
Name :
Sex : Age :
D.O.Birth :
05/25/2017
12:19:47
SCV:1
Cr:N Bc:A5
C:3 Z:1.0



Physician :
Comment :

W:256 L:128

20171228
Medi.R Technology

ID No. :
Name :
Sex : Age :
D.O.Birth :
05/25/2017
12:19:53
SCV:1
Cr:N Bc:A5
C:3 Z:1.0



Physician :
Comment :

W:256 L:128

증례- 후퇴시 식도 한번 더 관찰

20171228
Medi.R Technology

ID No. :
Name :

Sex : Age :
D.O.Birth :

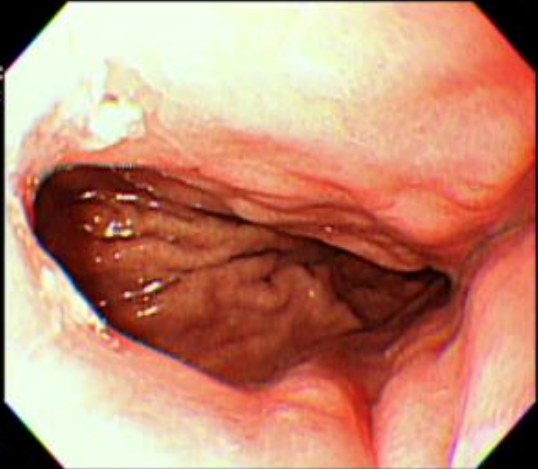
05/25/2017
12:19:53

SCV: 1

Cr: N Et: A5
Ce: 3 Z: 1.0

Physician :
Comment :

W:256 L:128



20171228
Medi.R Technology

ID No. :
Name :

Sex : Age :
D.O.Birth :

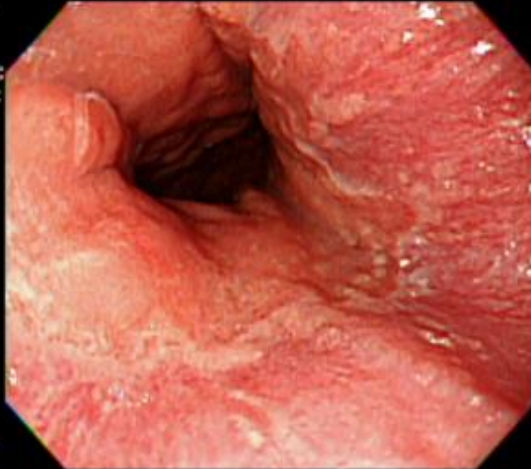
05/25/2017
12:19:56

SCV: 1

Cr: N Et: A5
Ce: 3 Z: 1.0

Physician :
Comment :

W:256 L:128



20171228
Medi.R Technology

ID No. :
Name :

Sex : Age :
D.O.Birth :

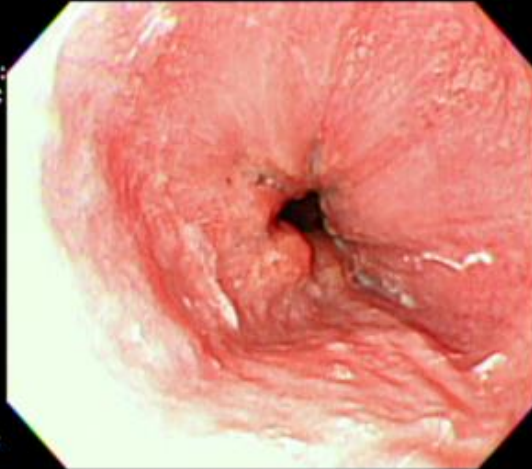
05/25/2017
12:20:00

SCV: 1

Cr: N Et: A5
Ce: 3 Z: 1.0

Physician :
Comment :

W:256 L:128



20171228
Medi.R Technology

ID No. :
Name :

Sex : Age :
D.O.Birth :


05/25/2017
12:20:02

SCV: 1

Cr: N Et: A5
Ce: 3 Z: 1.0

Physician :
Comment :

W:256 L:128



20171228
Medi.R Technology

ID No. :
Name :

Sex : Age :
D.O.Birth :

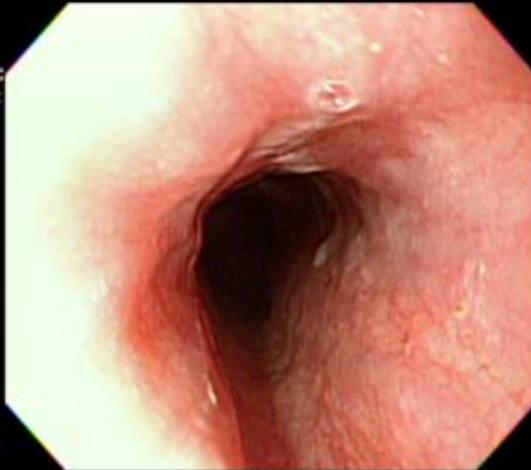
05/25/2017
12:20:05

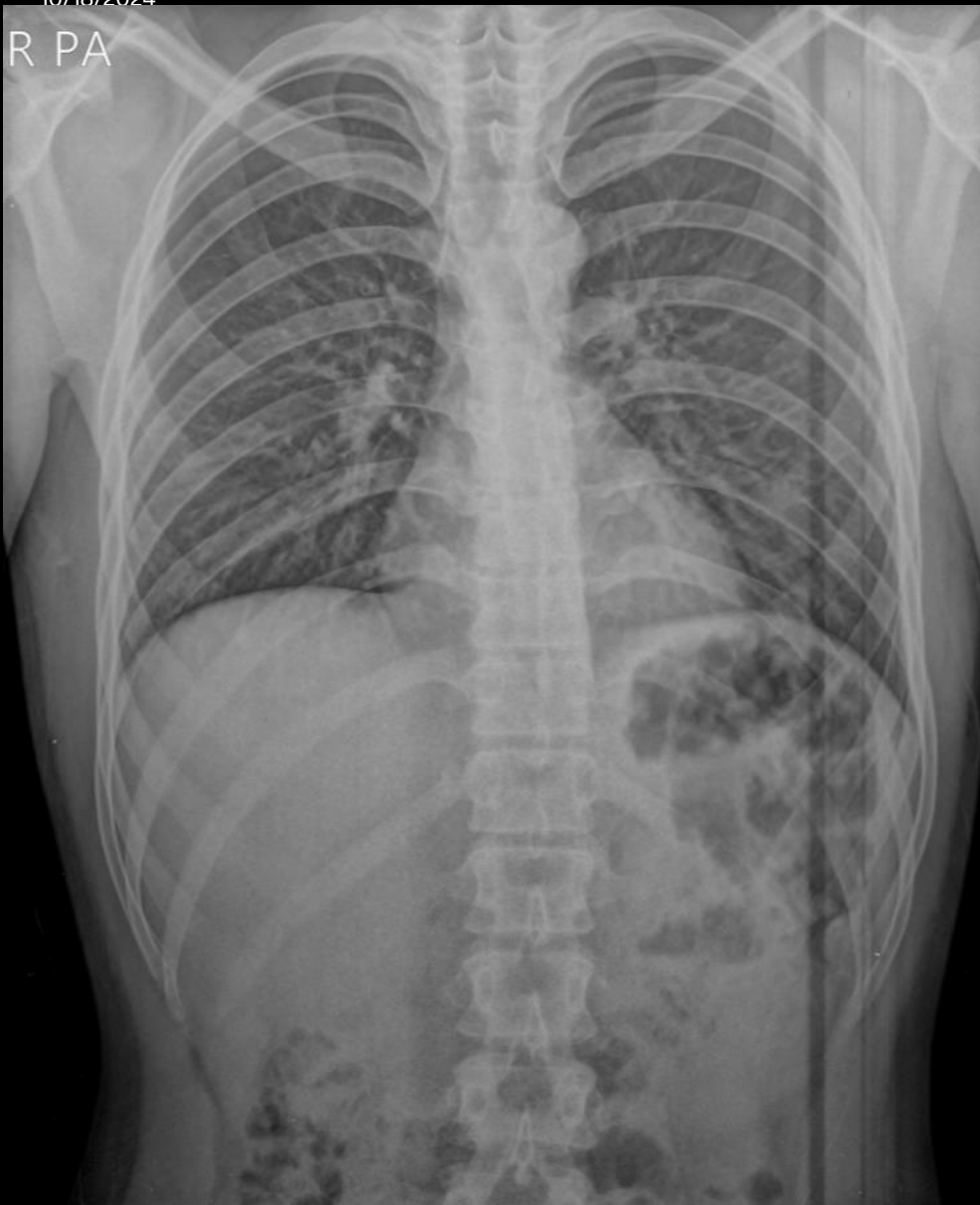SCV: 1

Cr: N Et: A5
Ce: 3 Z: 1.0

Physician :
Comment :

W:256 L:128





상병명	급성 위궤양			한국질병 분류기호	
	Acute Gastric ulcer Acute Duodenal ulcer r/o spontaneous microperforation of DU with peritonitis			K2531	
진료기간	2017년 2017년	12월 12월	26일 26일	부터 까지 ()일간	진료구분 외래
환자상태 및 진료소견	<p>상기 상병과 관련된 증상으로 진료의뢰 드립니다.</p> <p>금일 극심한 위통, 복통 주소로 내원한 환자입니다. 위내시경에서 acute GU, 1cm, acute Duodenal ulcer, deep 관찰됩니다. 복통 매우 심하면서 rigid abdomen 소견 보여 duodenal ulcer의 자발적인 미세 천공가능성 있으며, 이에 대해 복부 CT 등 적극적인 검사가 필요한 상황입니다. 금식 상태 유지하도록 지시하였으며, 급성 복통에 대한 further evaluation 필요합니다.</p> <p>본인은 병원에서 진료받은 진료정보가 의뢰의사에게 제공되는 것에 동의합니다.</p>				

위궤양의 병기분류

위궤양은 점막근판(muscularis mucosa)을 통해 점막하층으로 진행된 위점막 결손으로 정의

ENDOTODAY, 이준행

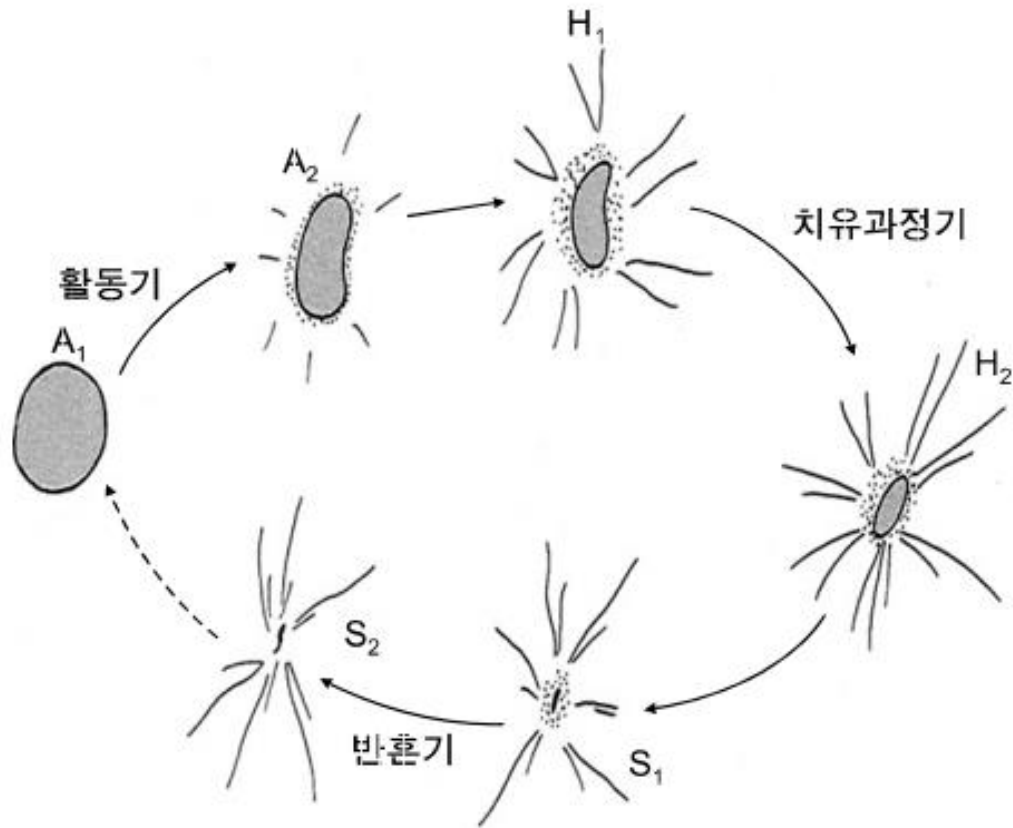
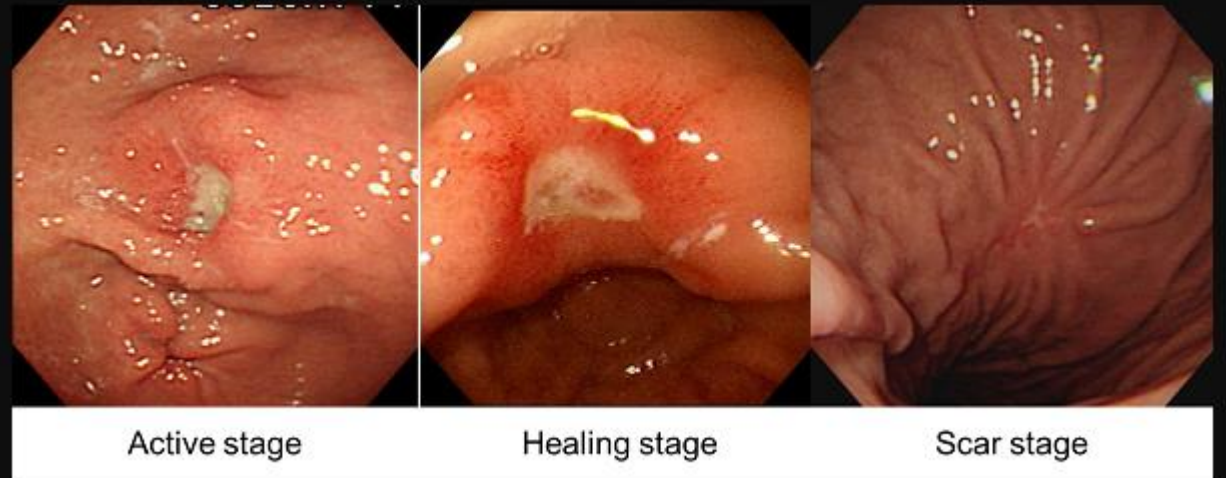
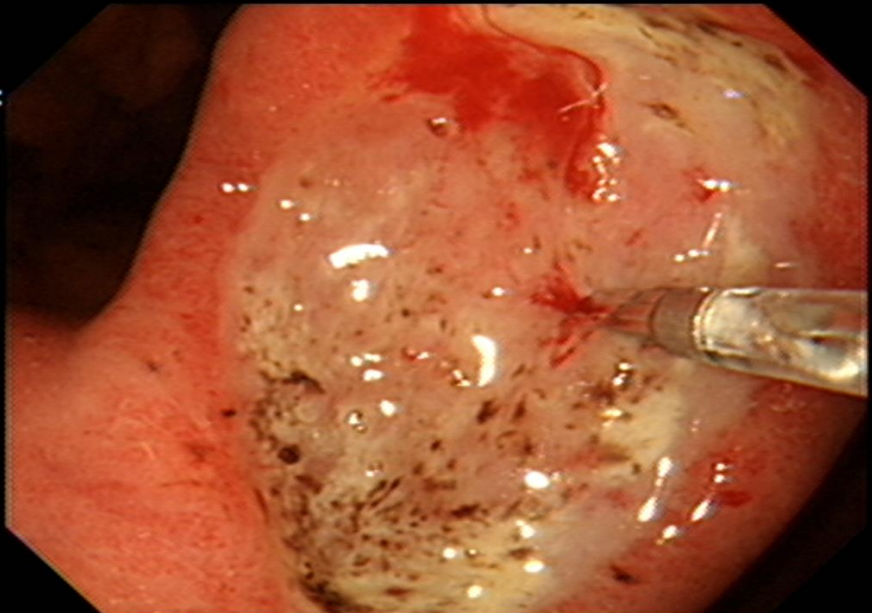
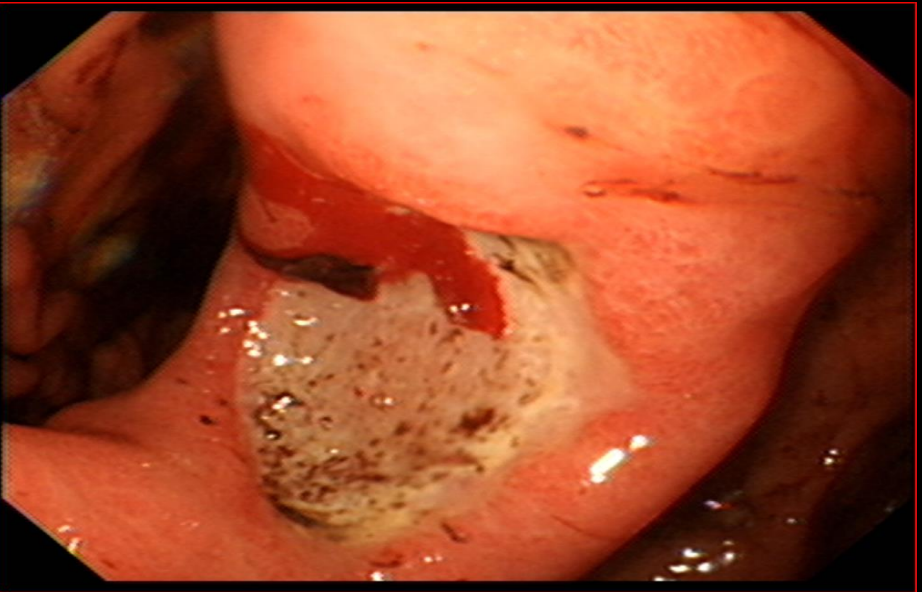
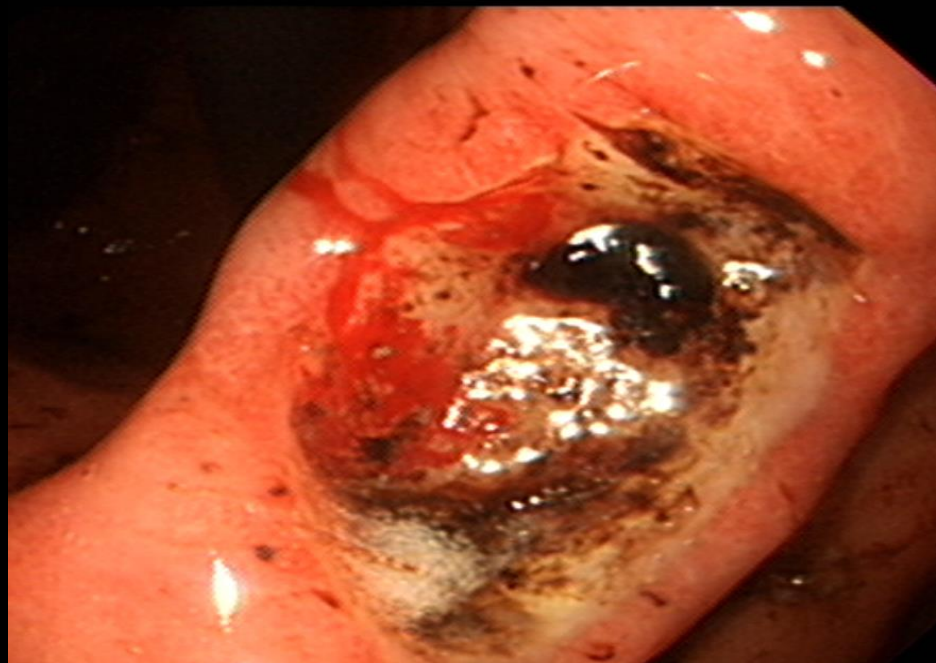
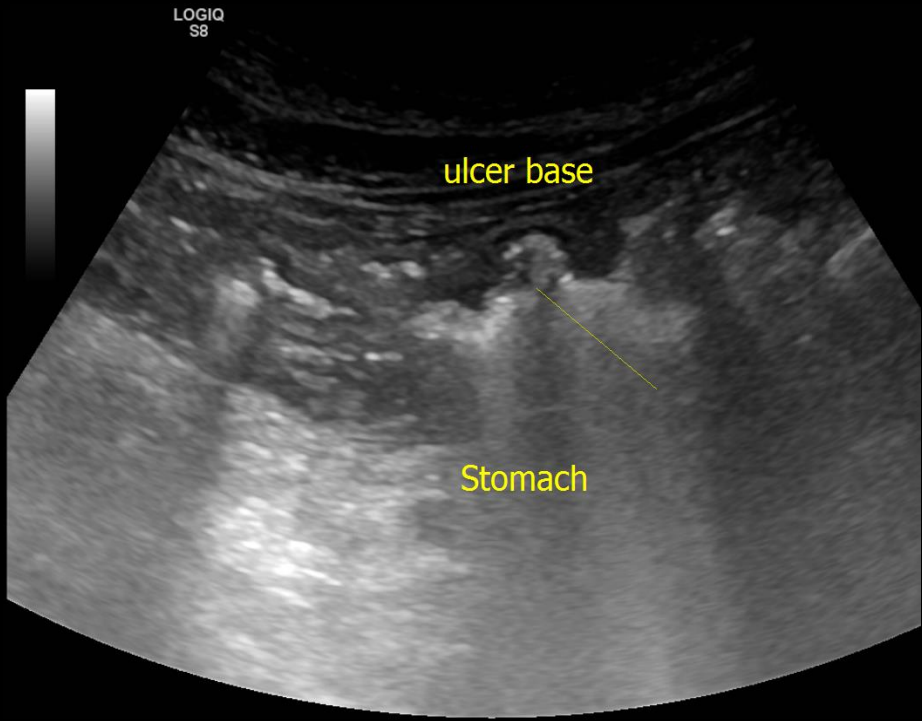
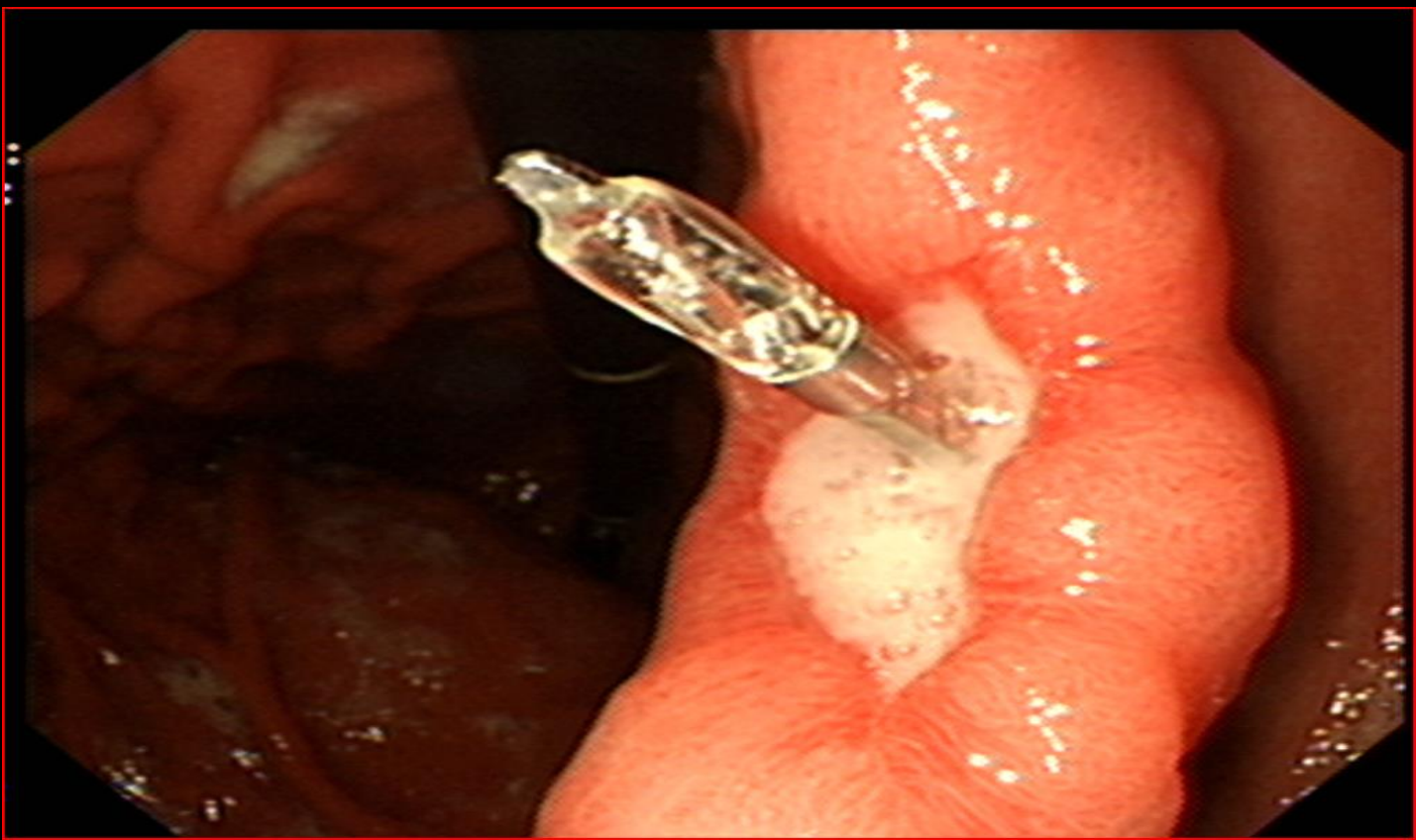
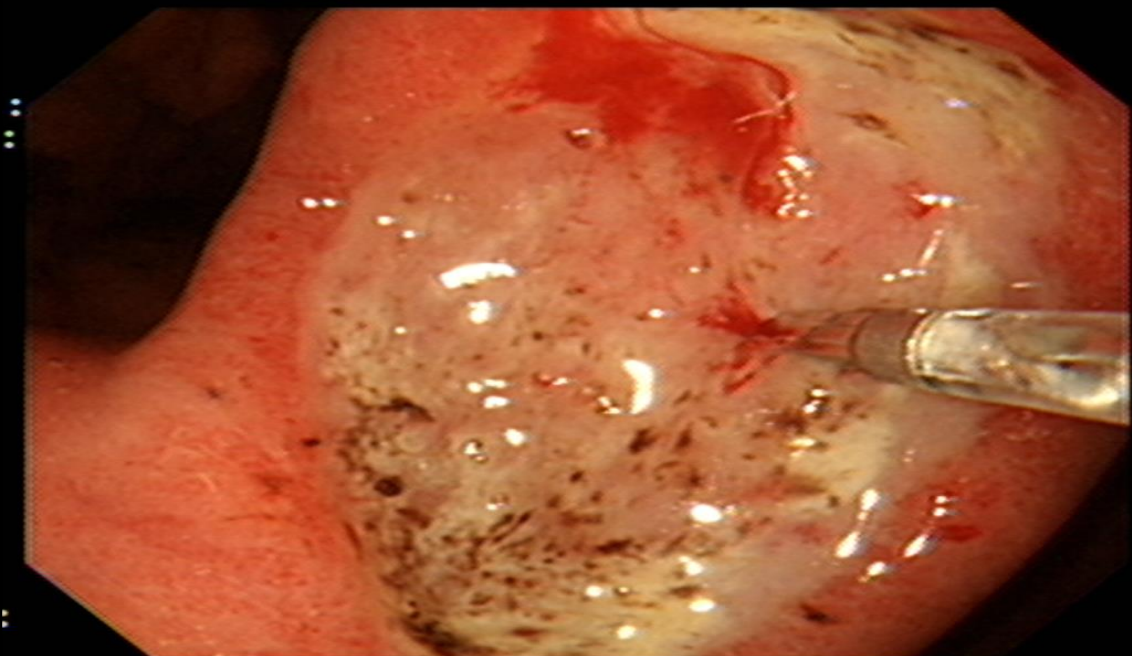


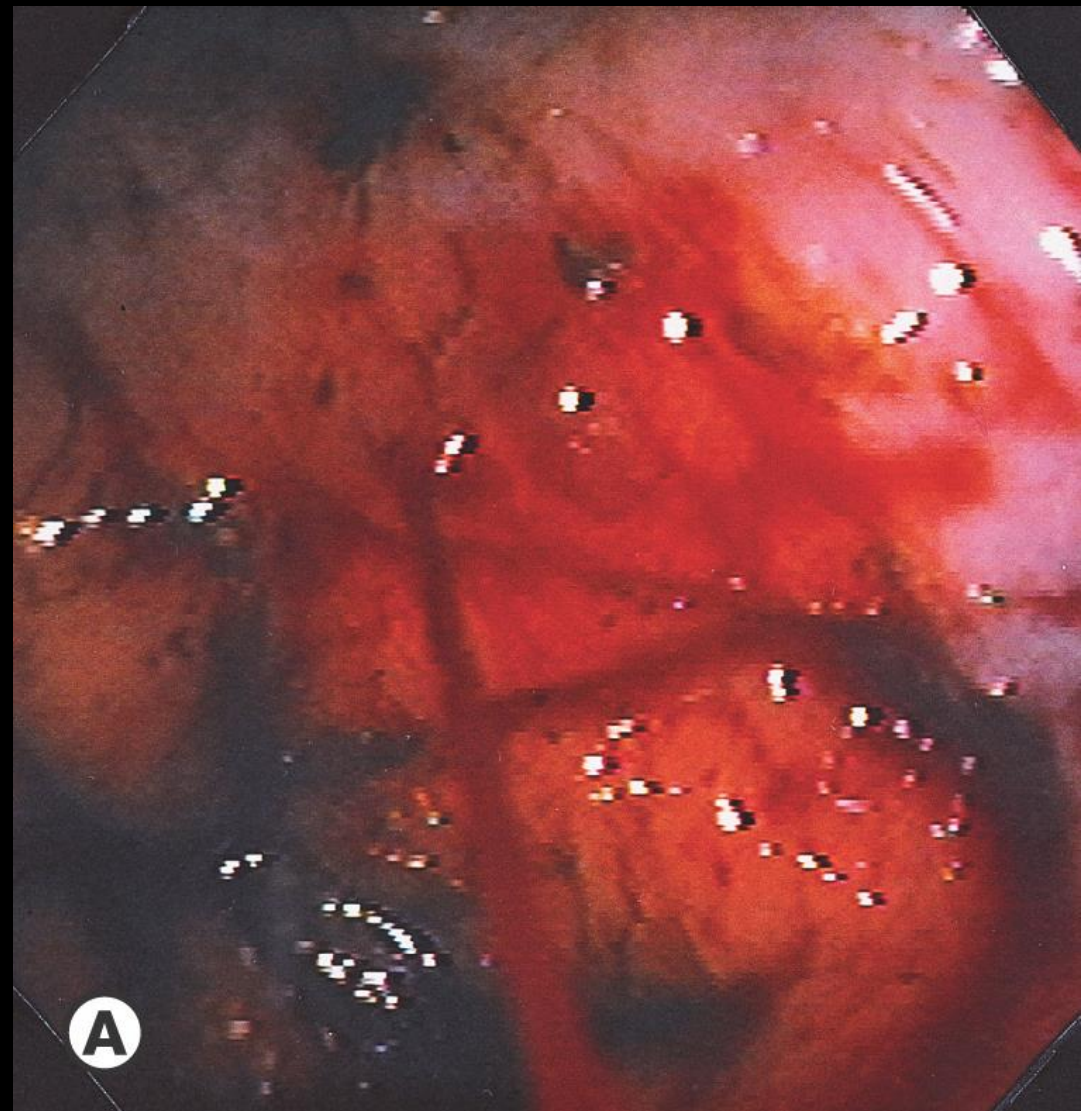
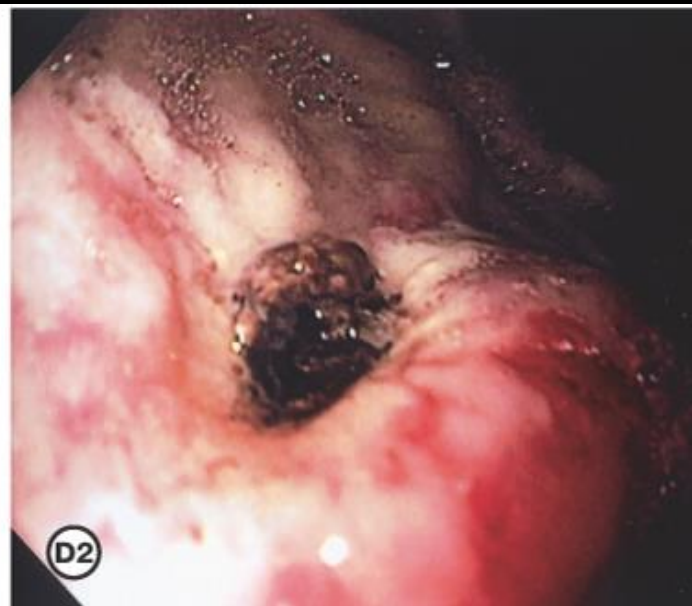
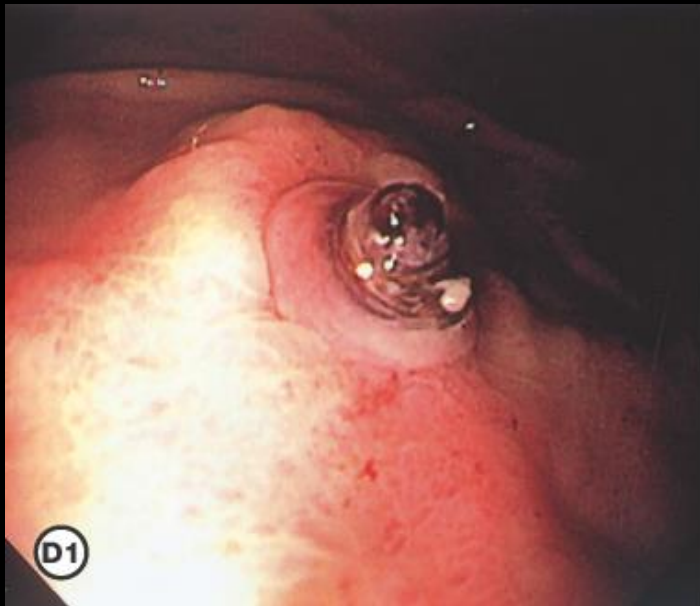
Figure 1. 궤양의 병기에 따른 형태 분류.



A1기: 백태가 두껍고 주변의 부종이 심하며,
 A2기: 백태가 얇아지면서 궤양의 변연이 선명
 H1기: 홍반 테가 궤양바닥의 주변에 관찰(재생 상피)
 H2기: 궤양 바닥의 패인 듯한 모양이 사라지고
 불규칙해지며 경계가 불분명해짐.
 S1기: 조직결손은 완전히 없어지고,
 붉은 색(모세혈관) 적색반흔기(red scar stage)
 S2기: 흔적인 점막의 주름만 남게 됨



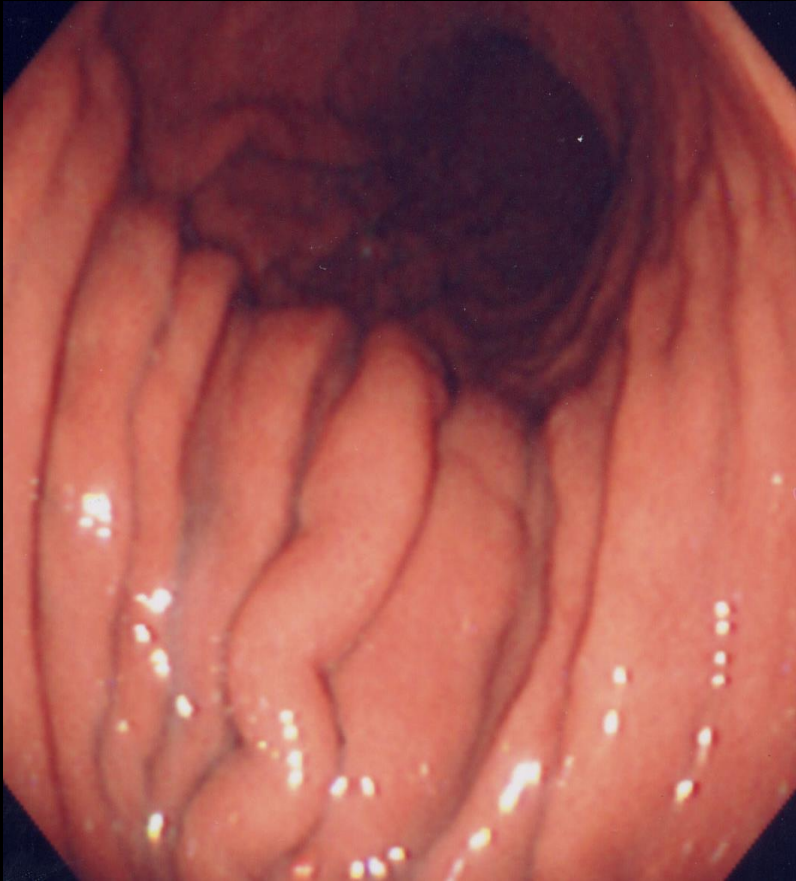



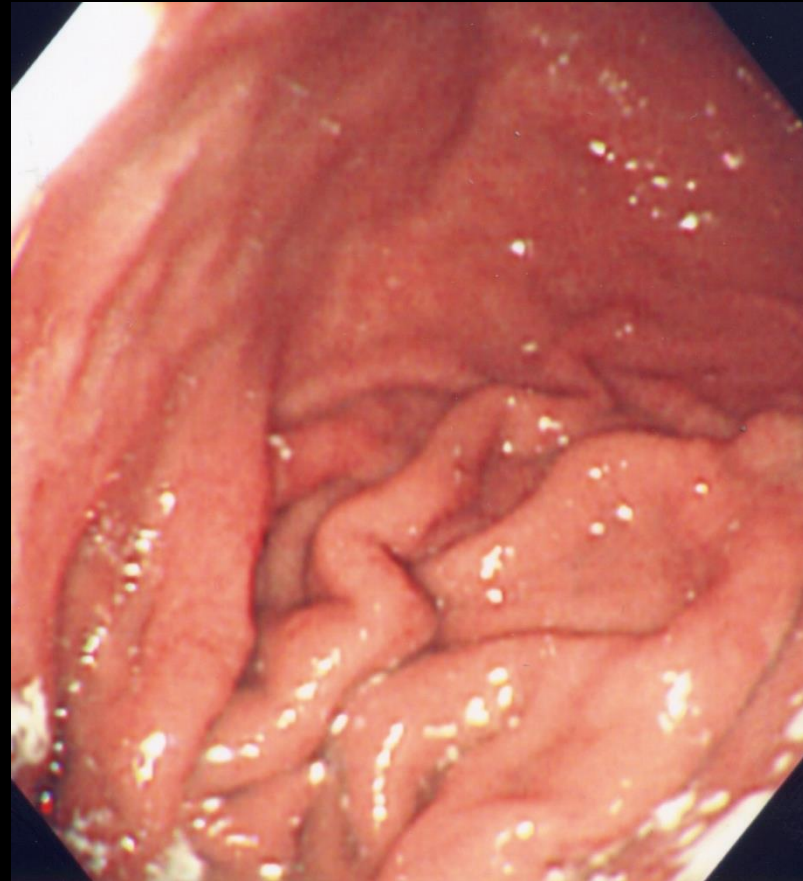
조기 위암을 발견하는 요령

- 비정상적으로 달리는 주름이 있나 살핀다
- EGCa 주름의 특징이 있나 살핀다
- 병변의 균일성이 소실되었나를 살핀다
- 세밀하게 관찰해서 미소 조기위암을 발견하려고 노력한다
- 계획을 가지고 일정하게 관찰하는 습관을 가진다
- 암이 조금이라도 의심이 되면 조직 생검을 시행한다
- 반드시 양성과 악성 둘 중 하나로 결정한다

첫째. 비정상적으로 달리는 주름이 있나 살핀다

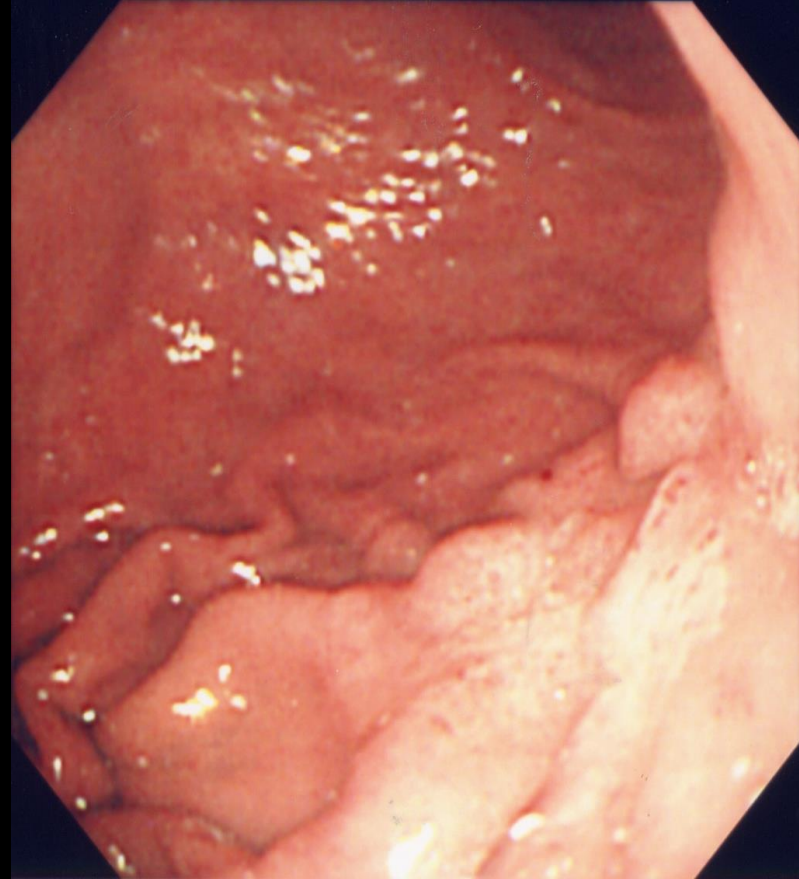
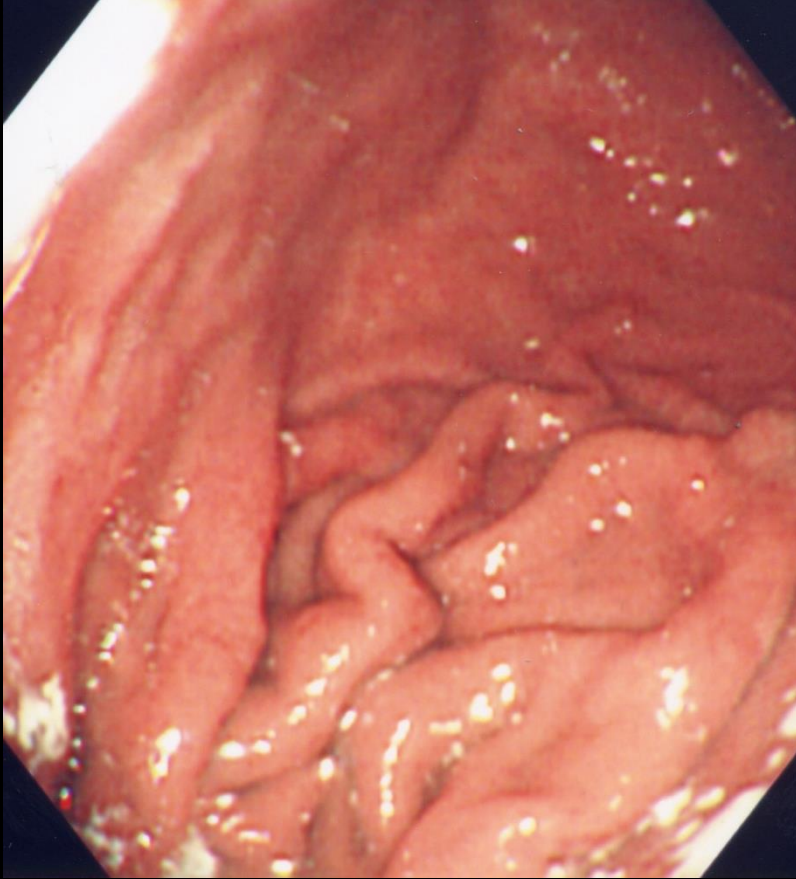

정상 주름

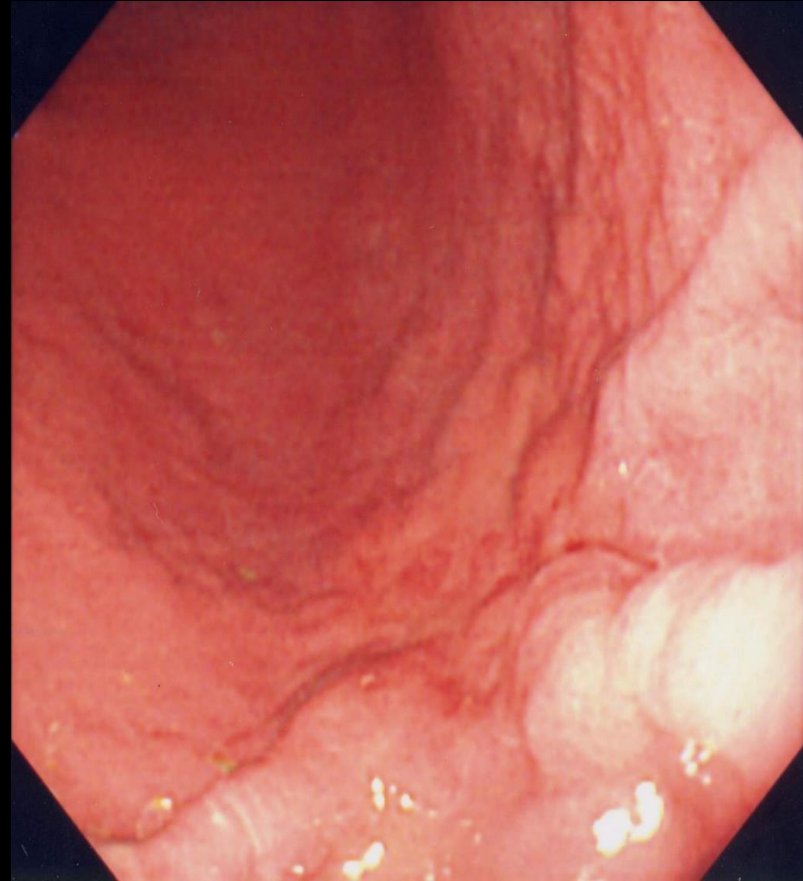
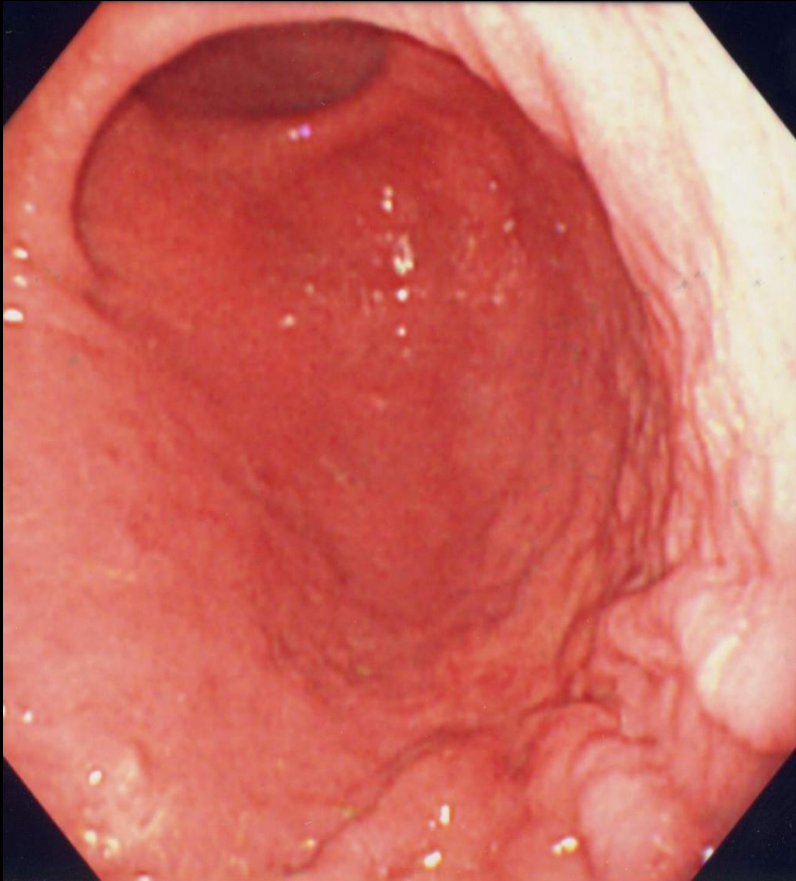


EGCA


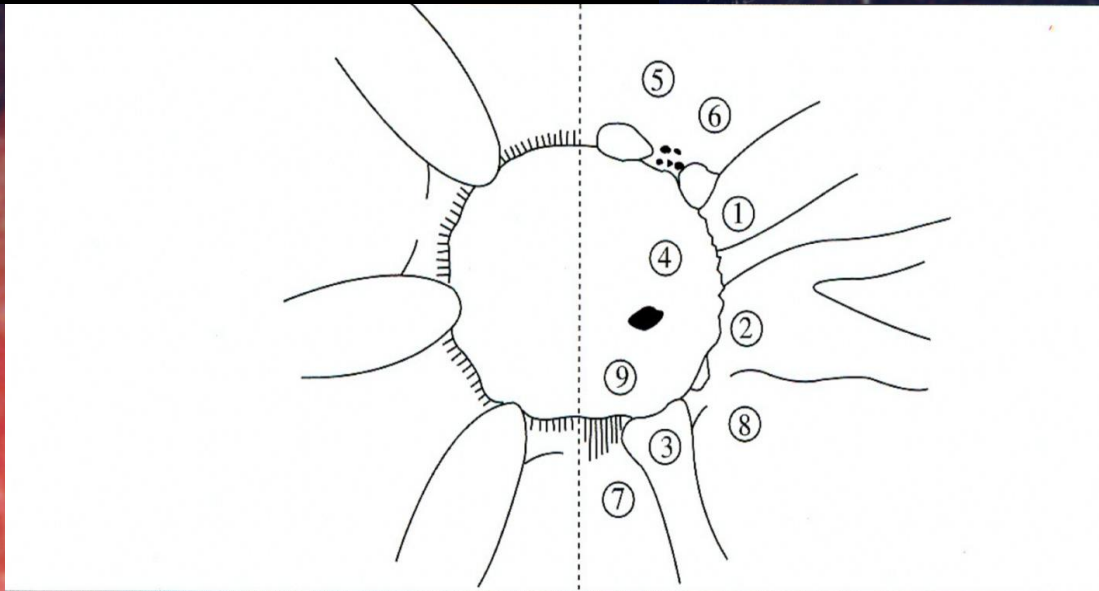
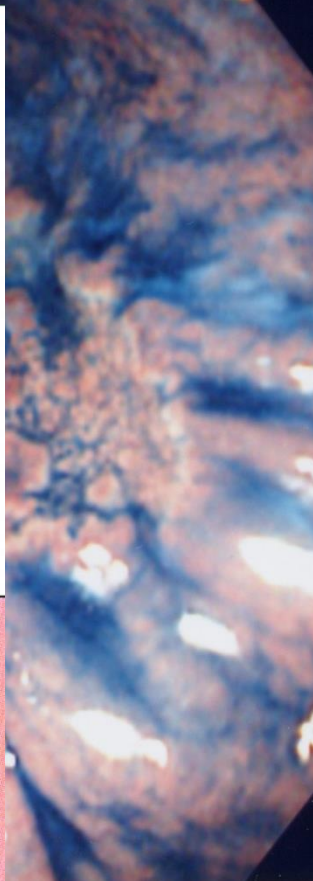
비정상적으로 달리는 주름



비정상적으로 달리는 주름



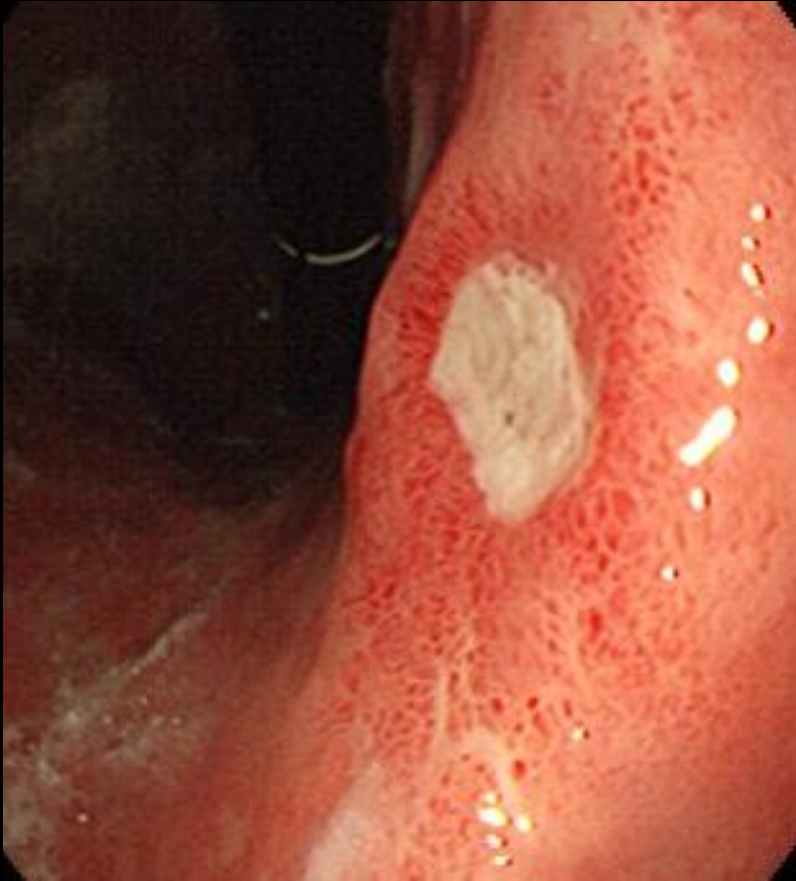
둘째, EGCa 주름의 특징이 있나 살핀다

		
<p>주 름</p>	<p>전원주를 따라 매우 균일 중심의 한 개 점으로 집합 변연이 평활</p>	<p>전원주에 균일하지 않은 경우가 많다. 중심이 한 개 점이 아닌 경우가 많다. 변연은 중도 절단 ① 융합 ② 등으로 나타난다. 근봉상 비대 ③</p>

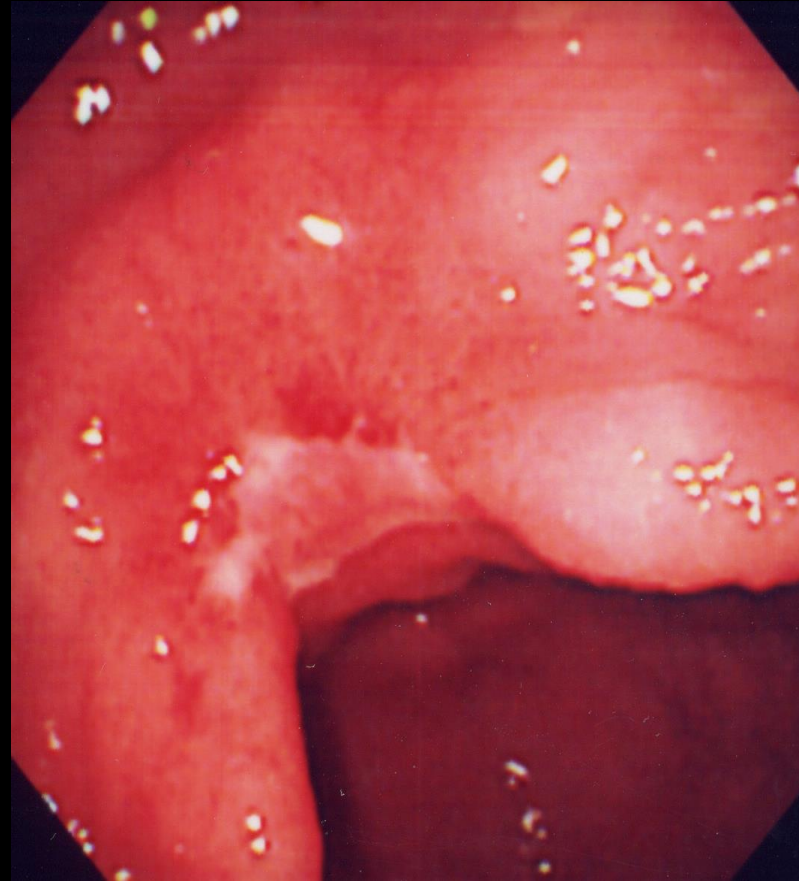
Gastric Ulcer

EGCa

셋째, 병변의 균일성이 소실되었나를 살핀다

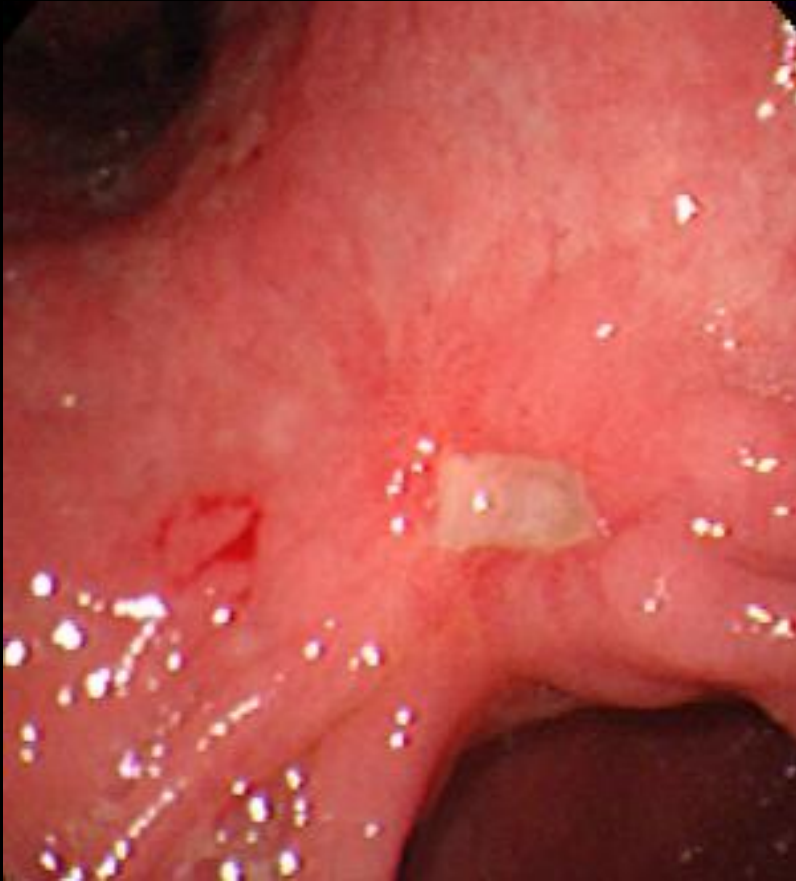

GU, H2

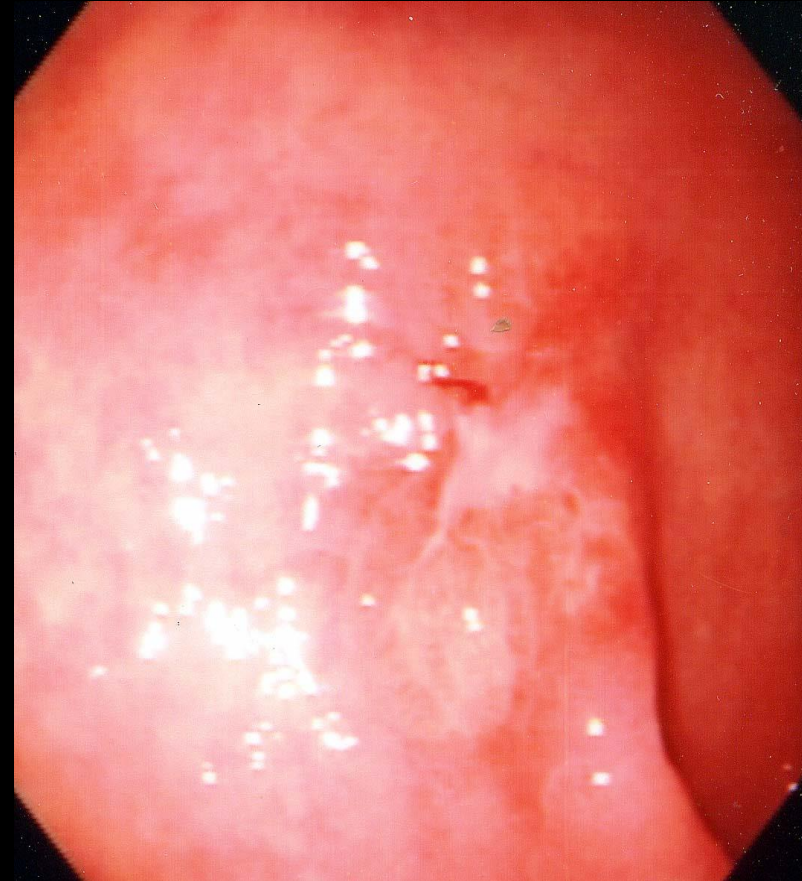


EGCA

불규칙한 재생상피의 혈관상

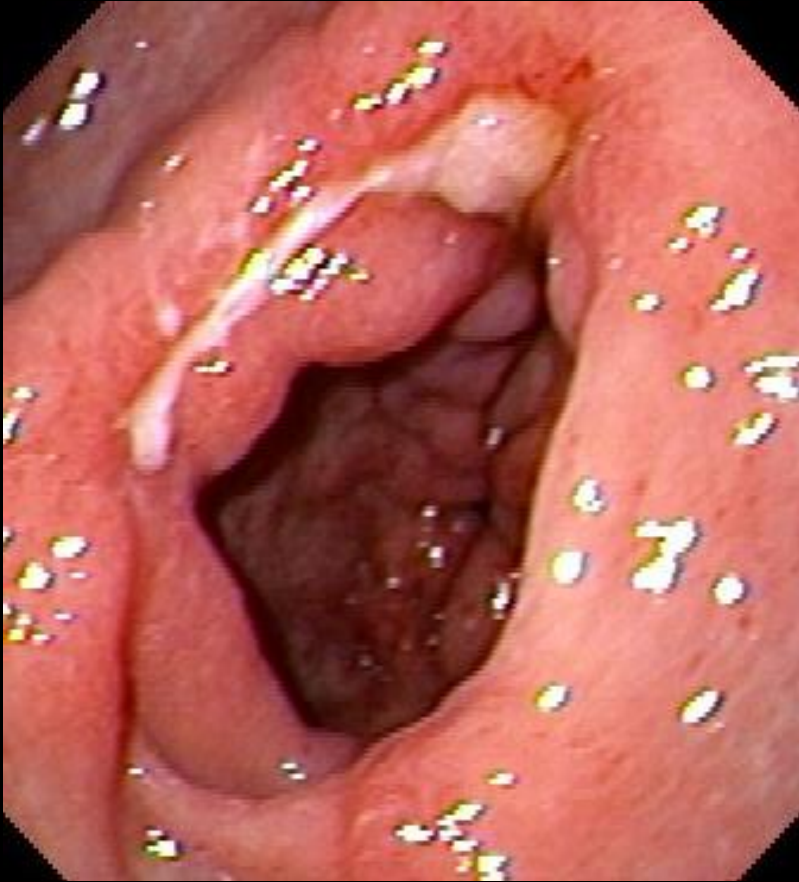

GU

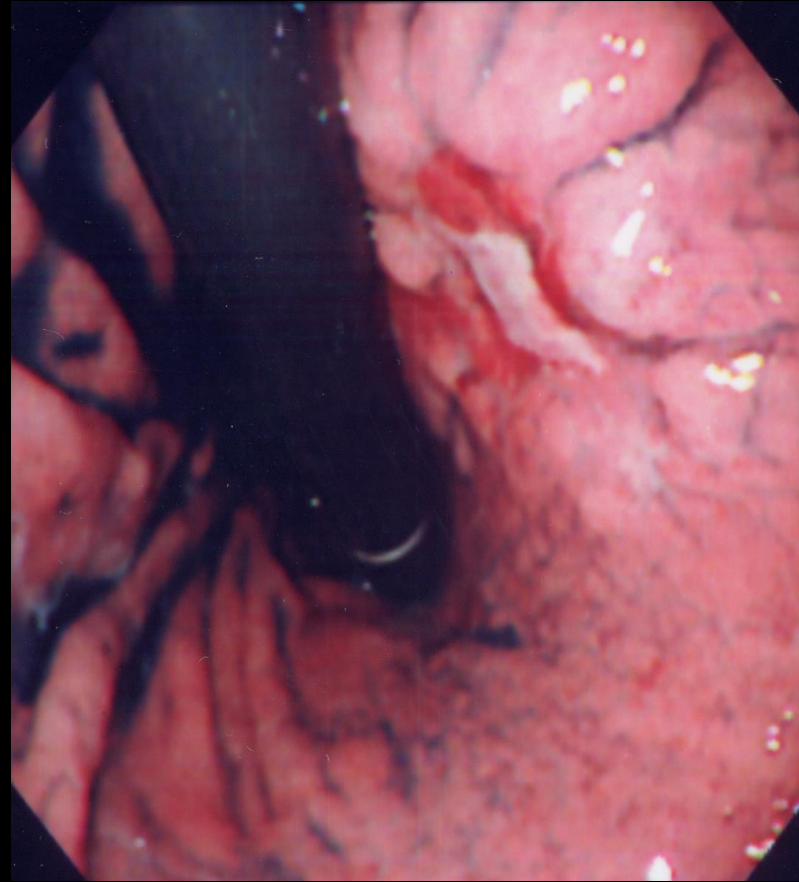


EGCA

Inharmonious and Inhomogeneous Growth

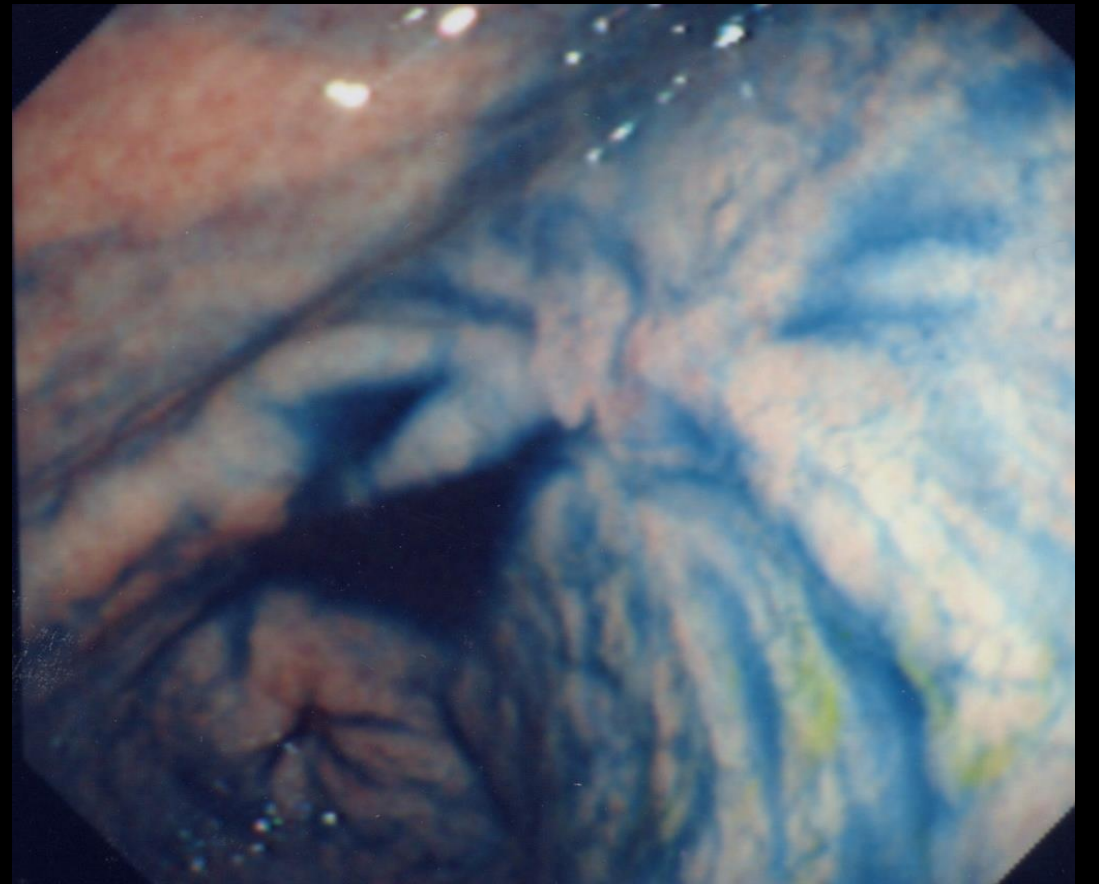
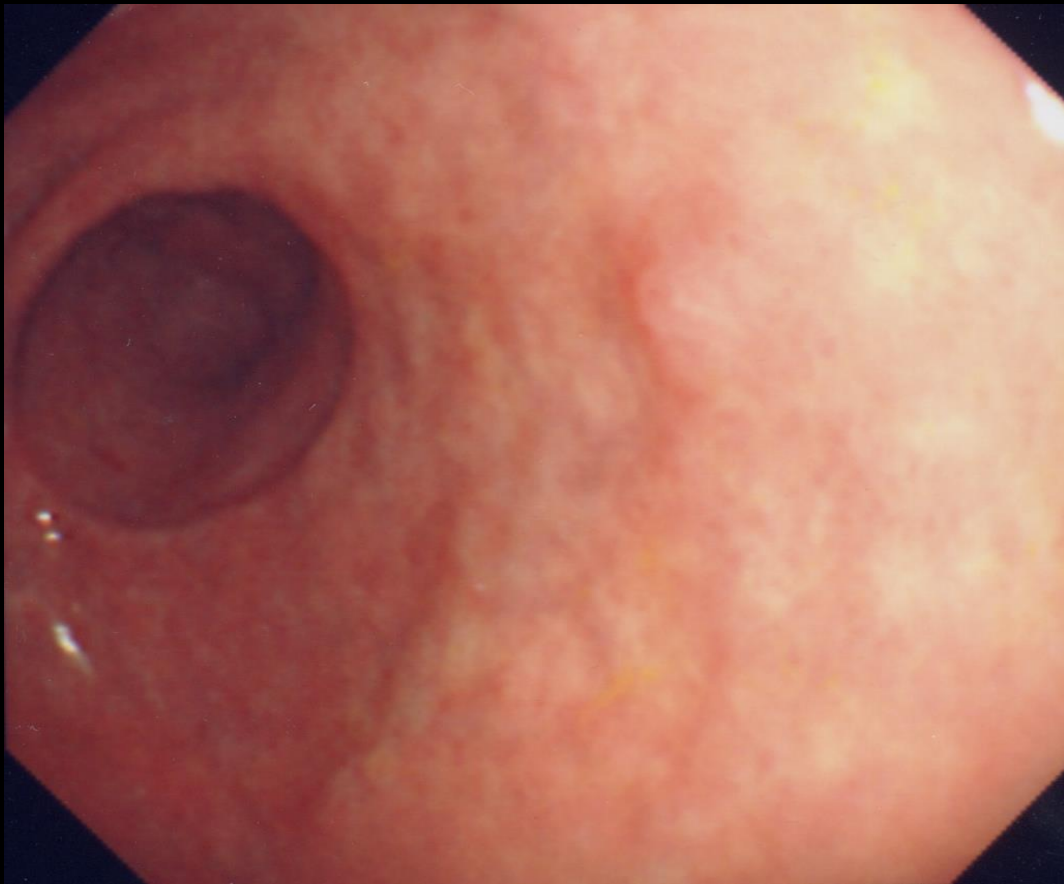


GU

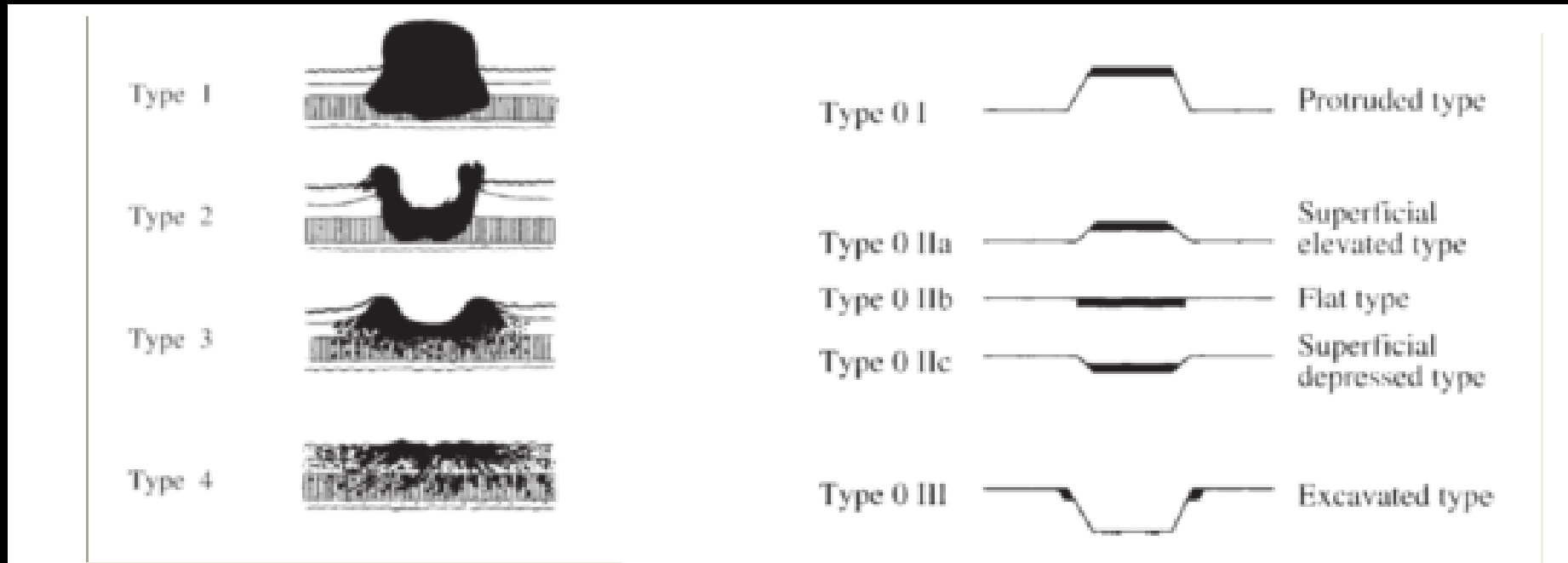


EGCA

조기위암 (M)



조기 위암의 형태적 분류



Advanced gastric cancer

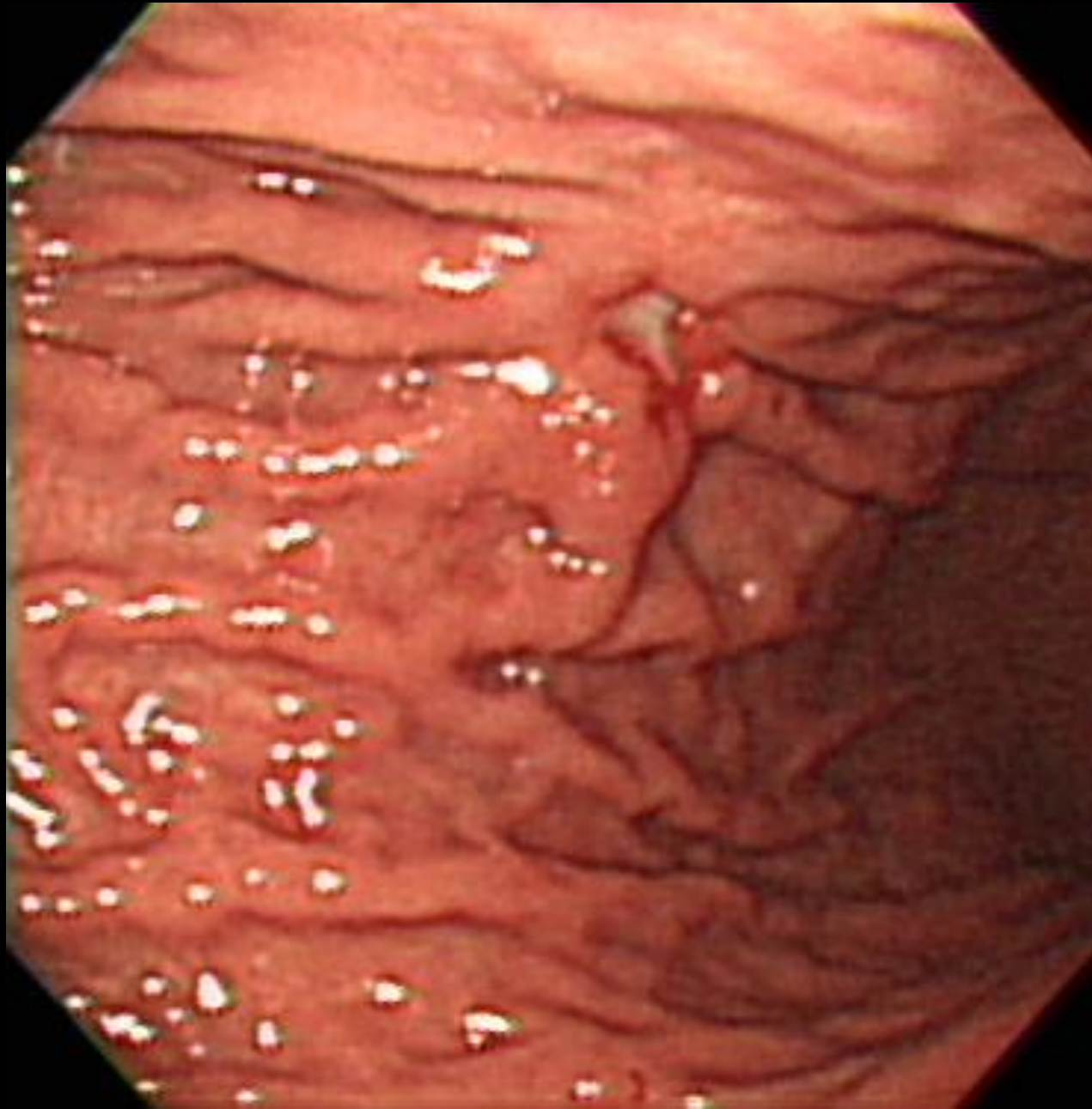
Borrmann type I-IV

type V : unclassified

Early gastric cancer (EGC)

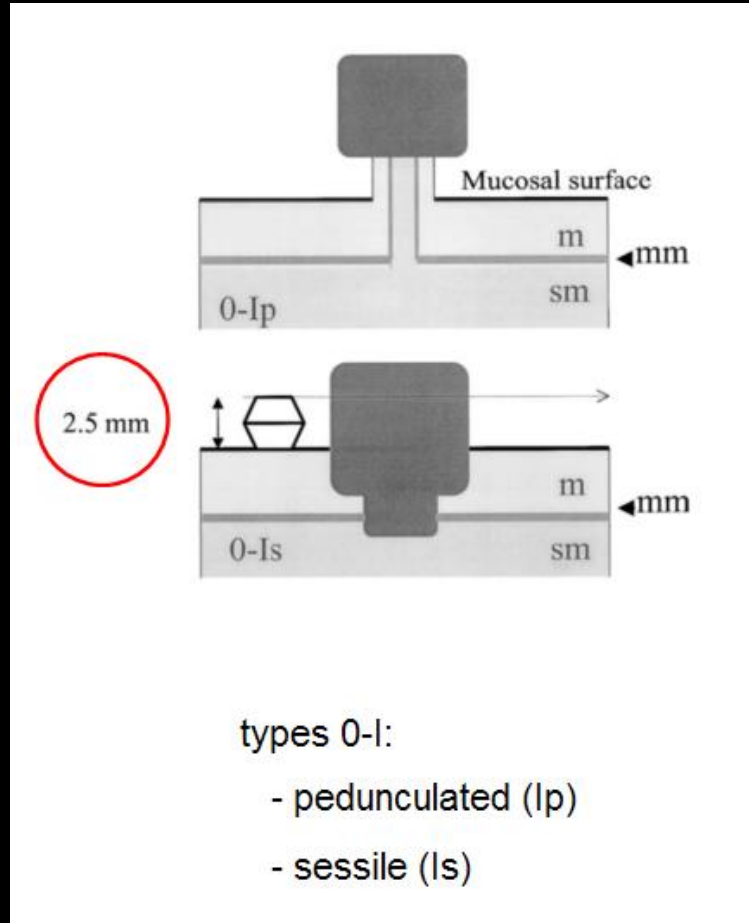
Type 0

10/18/2014
증례- r/o AGC, Bormann type III

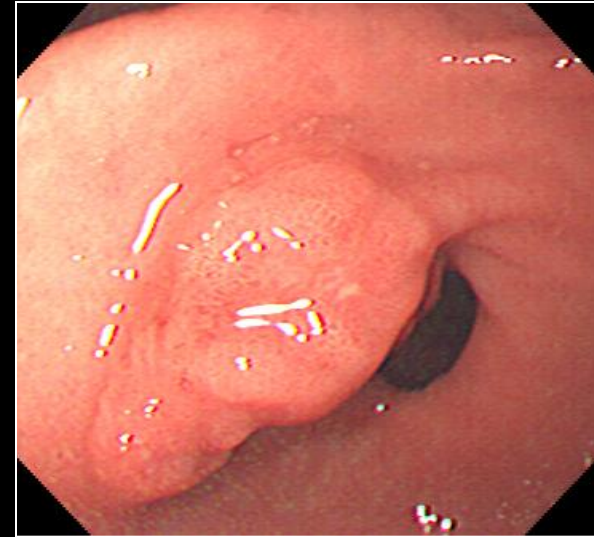


조기 위암의 형태적 분류

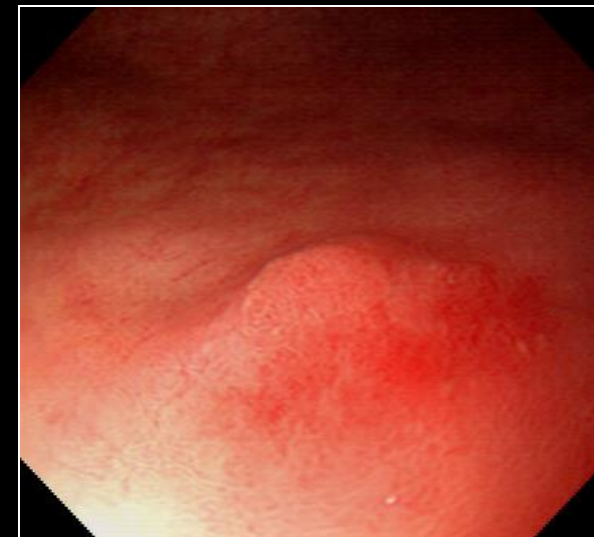Paris endoscopic classification of neoplastic lesions



EGCa I

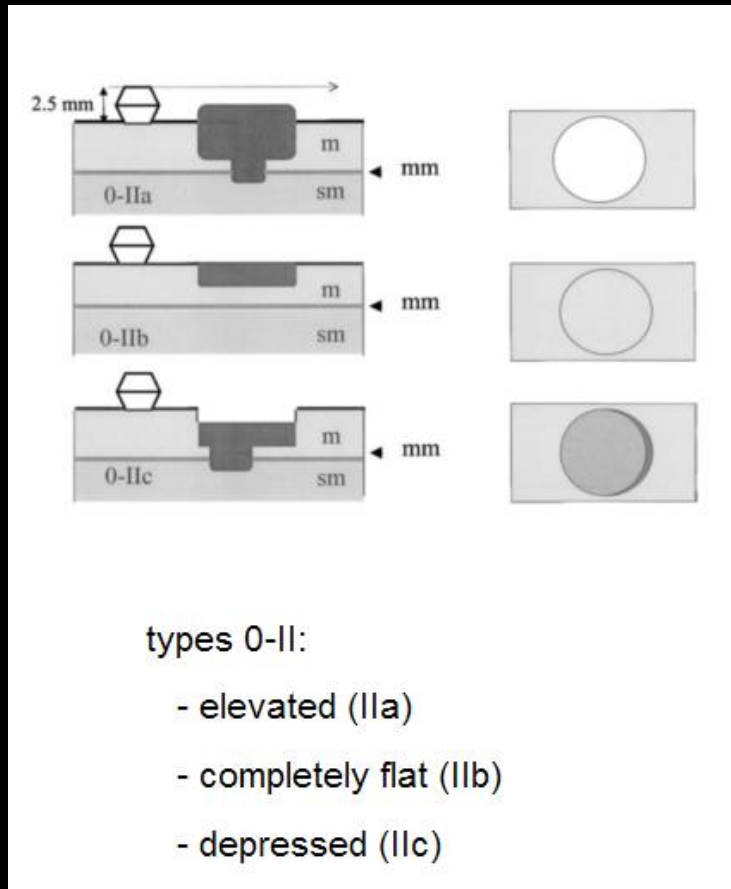


EGCa IIa

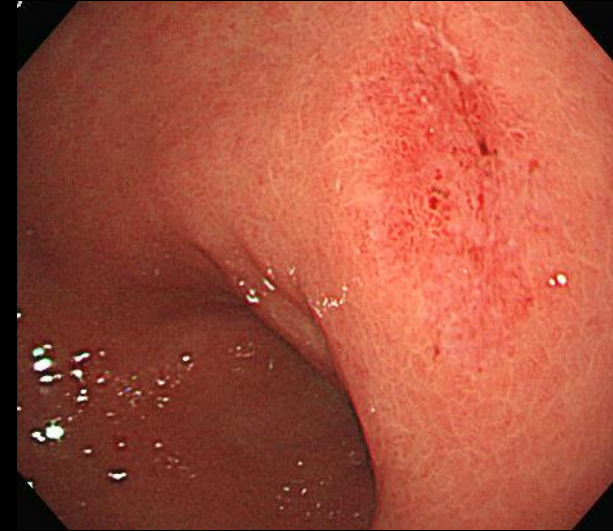


조기 위암의 형태적 분류

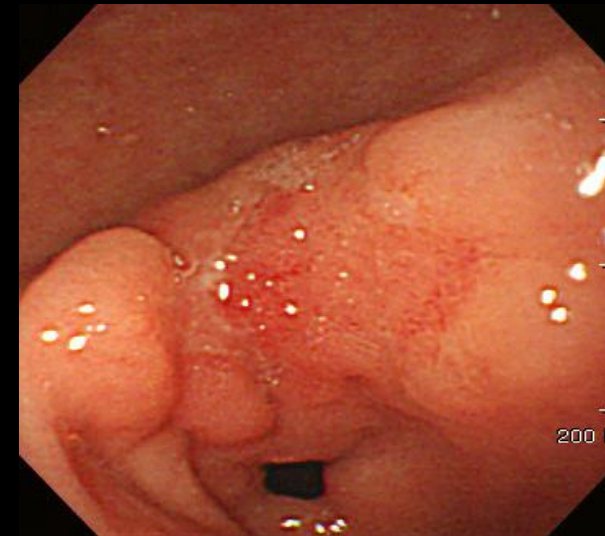Paris endoscopic classification of neoplastic lesions



EGCa IIb



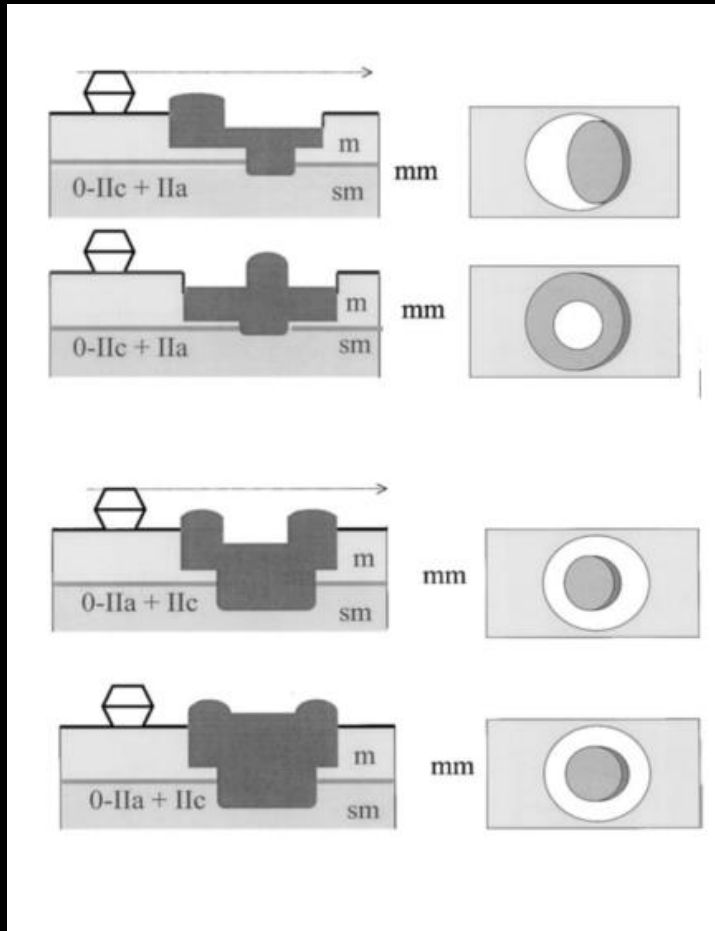
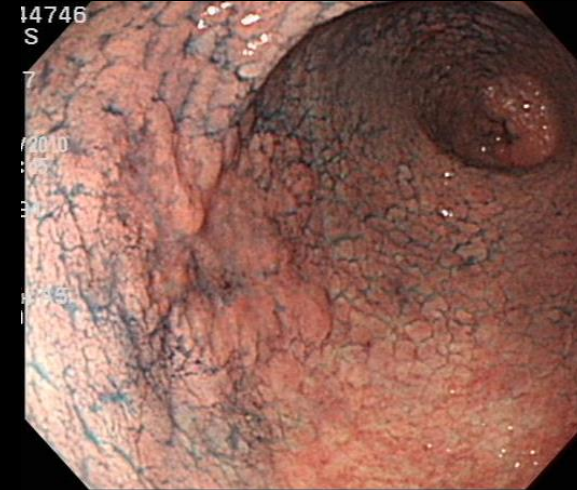
EGCa IIc



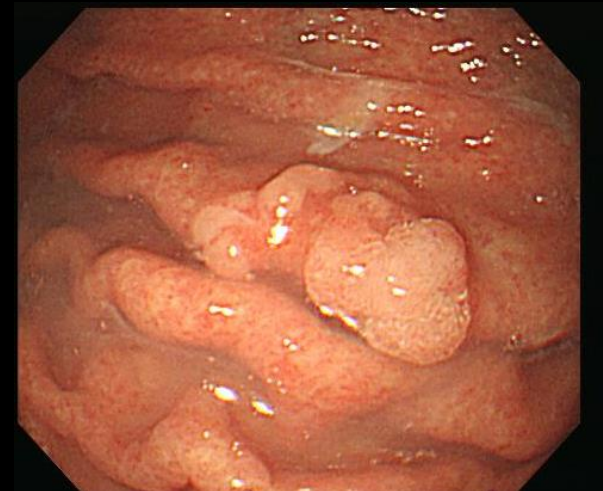
조기 위암의 형태적 분류

Paris endoscopic classification of neoplastic lesions

EGCa IIc+IIa

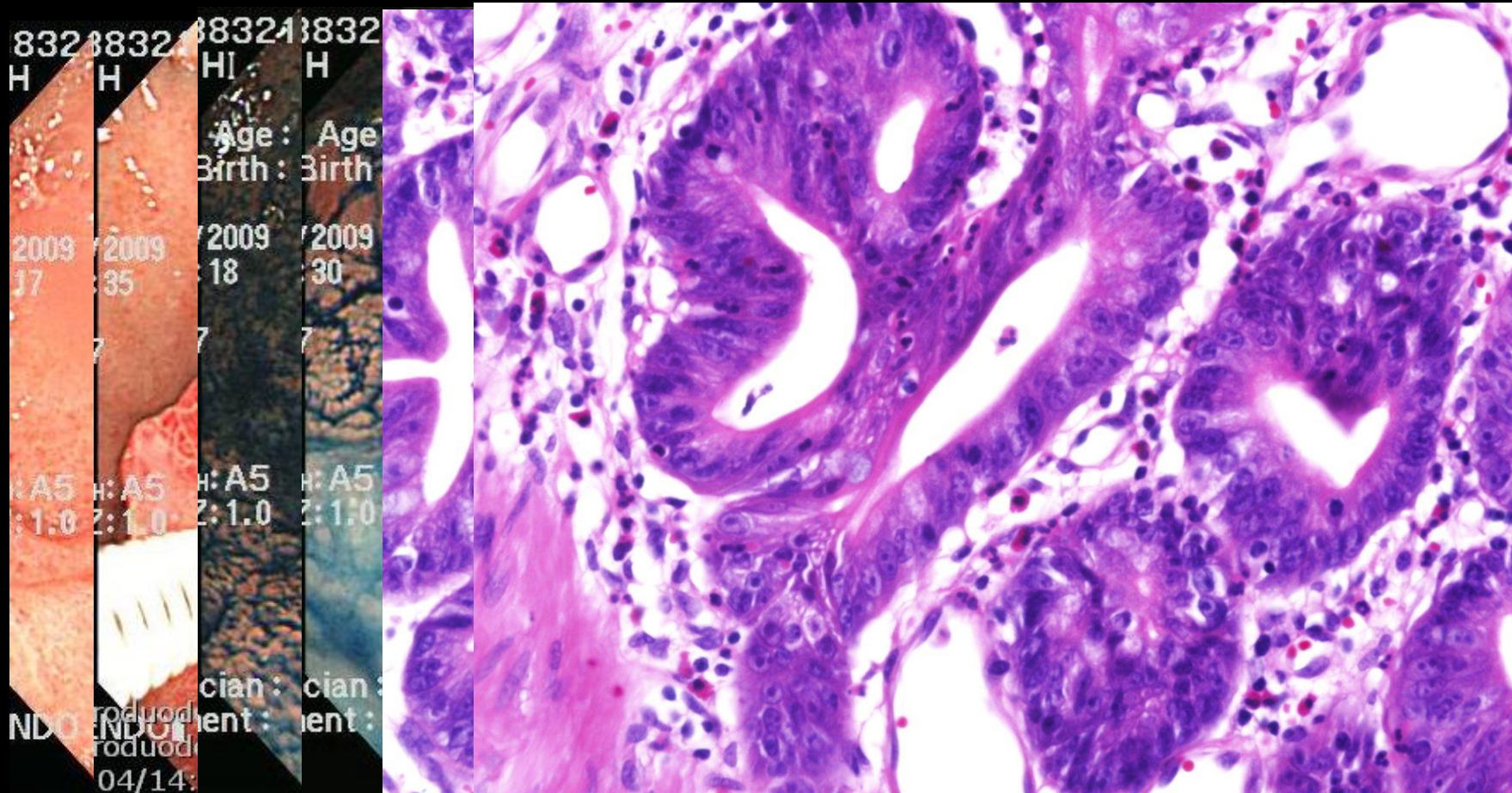


EGCa IIa+IIc



Biopsy negative인 경우에 육안적으로 malignancy를 시사하는 소견이 있으면 resection하여 관찰한다

1.4cm, pedunculated polyp=> Bx에서 hyperplastic polyp
=>EMR에서 intramural cancer



Dysplasia

(Robbins and Cotran's Pathologic basis of Diseases, 7th ed)

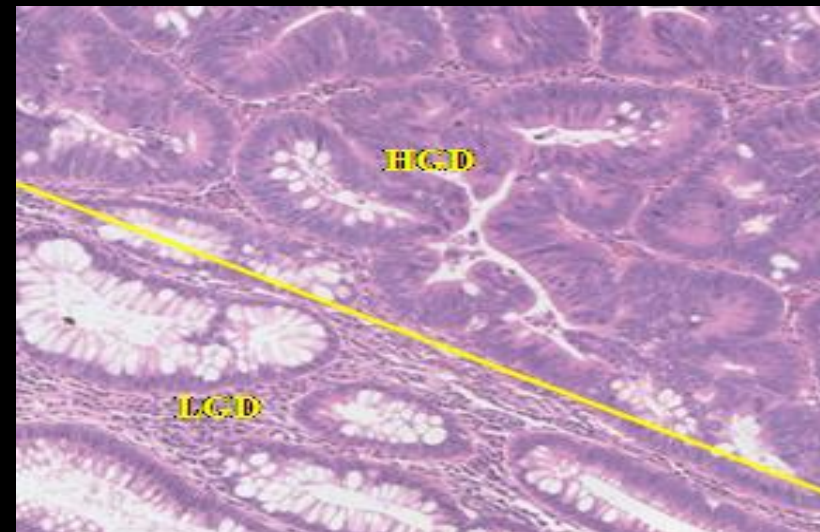
Dysplasia

Disordered growth

: A loss of uniformity of the individual cells as well as a loss in their architectural orientation

- Pleomorphism
- Hyperchromatic nuclei
- Increased mitotic figures, number and location

정상적으로 핵들이 baseline에 위치하나 dysplasia가 진행하면 길어지고, 층층이 쌓여서 위쪽으로 진행하면서 polarity를 소실하게 됨. 핵들의 높이가 Goblet cell의 높이의 50%이상 차지하게 되면 high grade로 판정



Dysplasia grades

Mild

Moderate

Severe

Carcinoma in situ

Polyps in the gastrointestinal tract: discrepancy between endoscopic forceps biopsies and resected specimens

Hye Young Sung^a, Dae Young Cheung^a, Se-Hyun Cho^a, Jin Il Kim^a, Soo-Heon Park^a, Joon-Yeol Han^a, Gyeong Sin Park^b, Jae Kwang Kim^a and In-Sik Chung^a

Table 2 Pathologic comparison between forcep biopsy results and resection biopsy results in gastric polyp (A) and colonic polyp (B)

A		Resection results				
Forcep biopsy results	Inflammatory polyp (n=29, 10.8%)	Hyperplastic polyp (n=126, 47%)	Adenoma with LGD (n=46, 17.2%)	Adenoma with HGD (n=42, 15.7%)	Adenocarcinoma (n=25, 9.3%)	
Inflammatory polyp (n=63, 23.5%)	12	40	8	3	0	
Hyperplastic polyp (n=97, 36.2%)	7	86	3	0	1	
Adenoma with LGD (n=55, 20.5%)	6	0	29	16	4	
Adenoma with HGD (n=37, 13.8%)	1	0	6	23	7	
Adenocarcinoma (n=16, 6.0%)	3	0	0	0	13	

B		Resection results				
Forcep biopsy results	Inflammatory polyp (n=111, 11.1%)	Hyperplastic polyp (n=44, 4.4%)	Adenoma with LGD (n=559, 56.1%)	Adenoma with HGD (n=229, 23%)	Adenocarcinoma (n=53, 5.3%)	
Inflammatory polyp (n=77, 7.7%)	27	22	23	3	2	
Hyperplastic polyp (n=39, 3.9%)	17	15	6	1	0	
Adenoma with LGD (n=683, 68.6%)	63	7	462	142	9	
Adenoma with HGD (n=181, 18.2%)	4	0	67	82	28	
Adenocarcinoma (n=16, 1.6%)	0	0	1	1	14	

The Kendall's tau-b and the κ coefficient for agreement between the EFB and resected specimen of gastric polyp were 0.577 and 0.472 (P value <0.001), respectively. The Kendall's tau-b and the κ coefficient for agreement between the EFB and resected specimen of colon polyp were 0.479 and 0.293 (P value <0.001), respectively. EFB, endoscopic forceps biopsy; HGD, high-grade dysplasia; LGD, low-grade dysplasia.

Results Multiple polyps existed in 31.6% of the patients. The pathological diagnoses of resected gastric polyps were as follows: adenomas with low-grade dysplasia, 46 (17.2%); adenomas with high-grade dysplasia, 42 (15.7%); hyperplastic polyps, 126 (47.0%); chronic inflammatory polyps, 29 (10.8%); and adenocarcinomas, 25 (9.3%). The discrepancy rate between an EFB and the pathology of the resected gastric polyps was 39.2% (the Kendall's tau-b and the κ coefficient for agreement between the EFB and resected specimens of gastric polyps were 0.577 and 0.472, respectively; P value <0.001). No relationship between the

European Journal of Gastroenterology & Hepatology 2009, 21:190–195

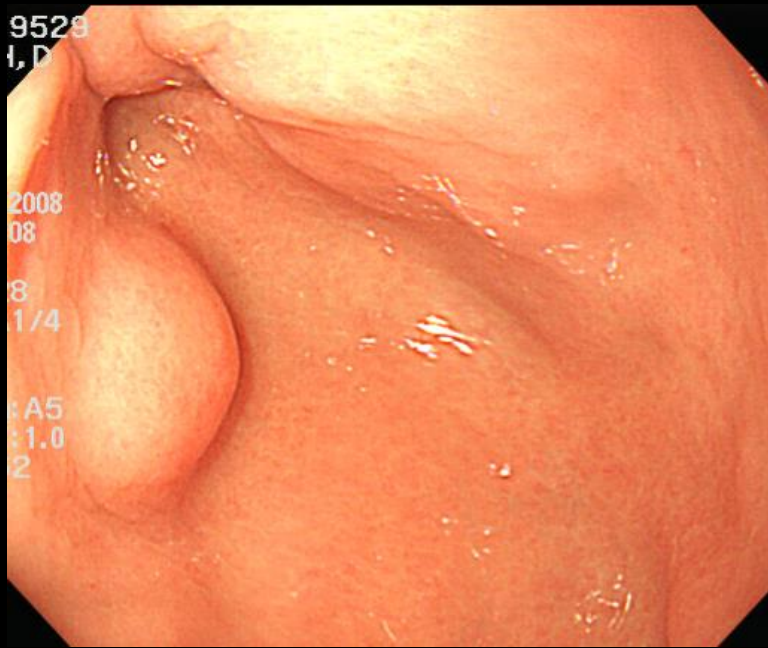
Keywords: concordance, forceps biopsy, pathology, polyp

Division of Gastroenterology, Departments of ^aInternal Medicine and ^bClinical Pathology, The Catholic University of Korea, Seoul, Korea

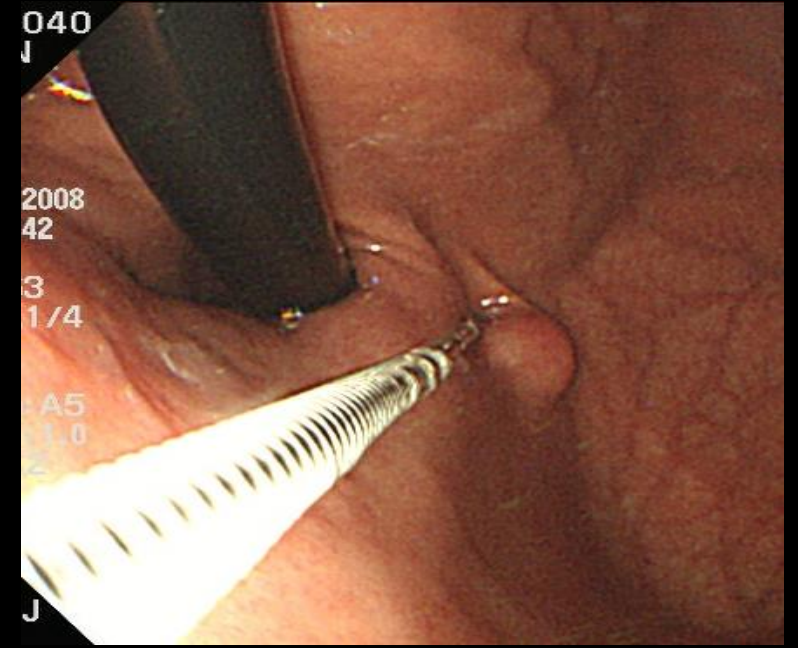
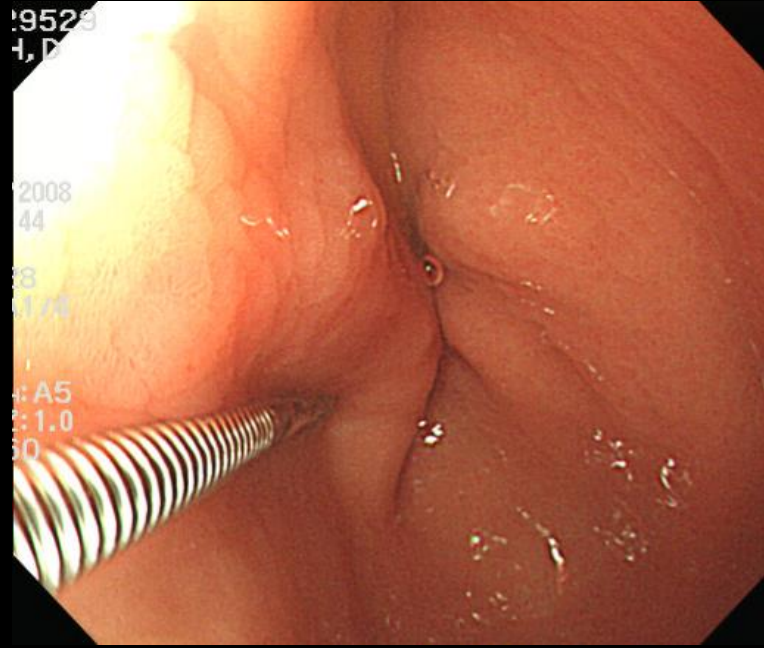
Correspondence to Dr Dae Young Cheung, MD, Department of Internal Medicine, Division of Gastroenterology, St. Mary's Hospital, The Catholic University of Korea College of Medicine, Seoul 150-173, Korea
Tel: +82 2 3779 1328; fax: +82 2 3779 1331;
e-mail: adagio@catholic.ac.kr

Received 28 April 2008 Accepted 7 August 2008

병변의 특징을 관찰

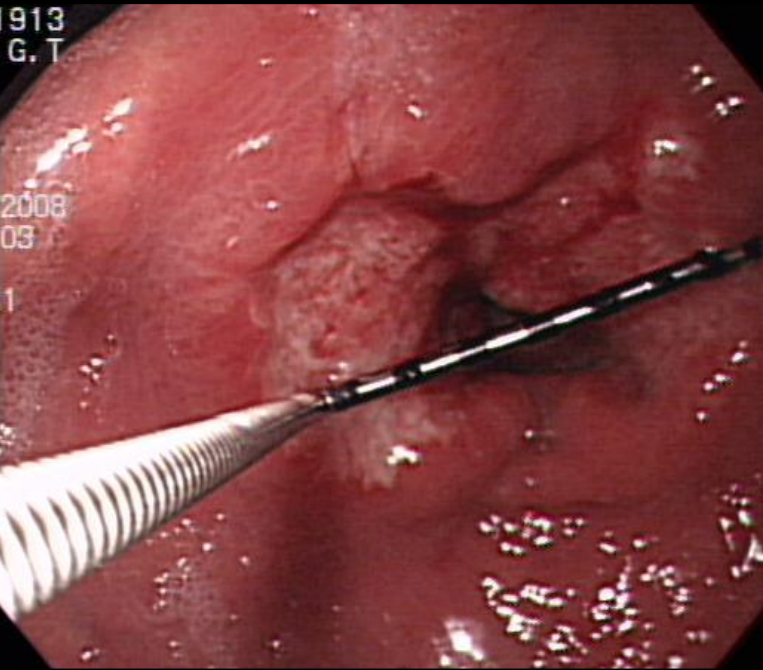


Lipoma: cushion sign

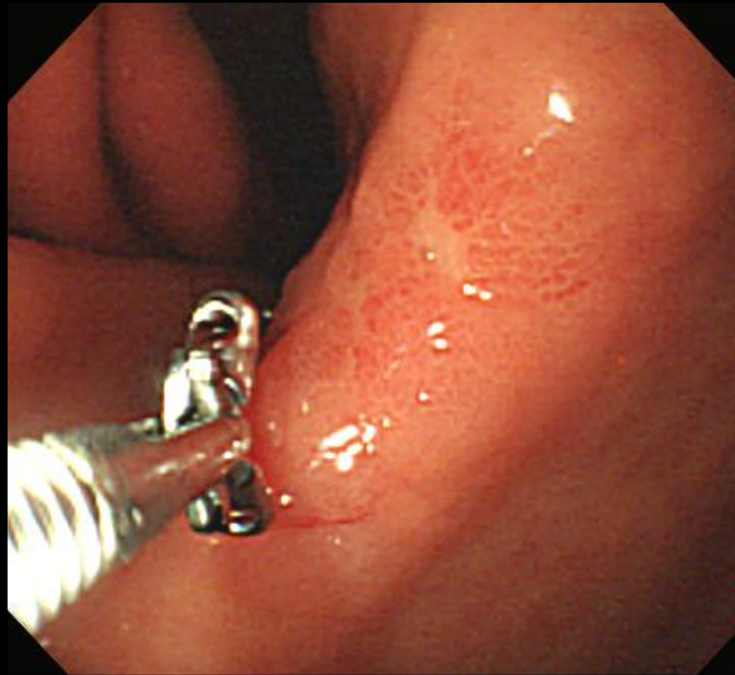


GIST : rolling sign

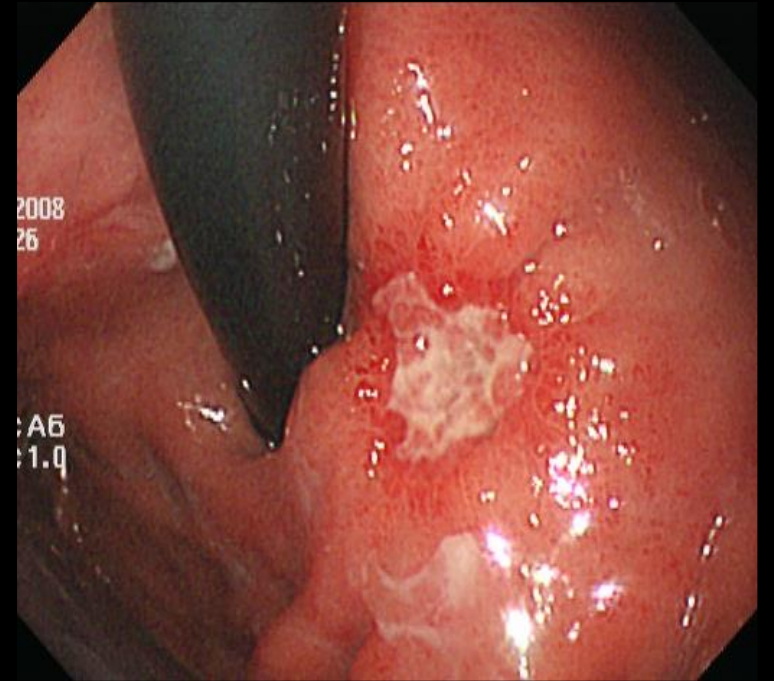
병변의 크기



내시경자

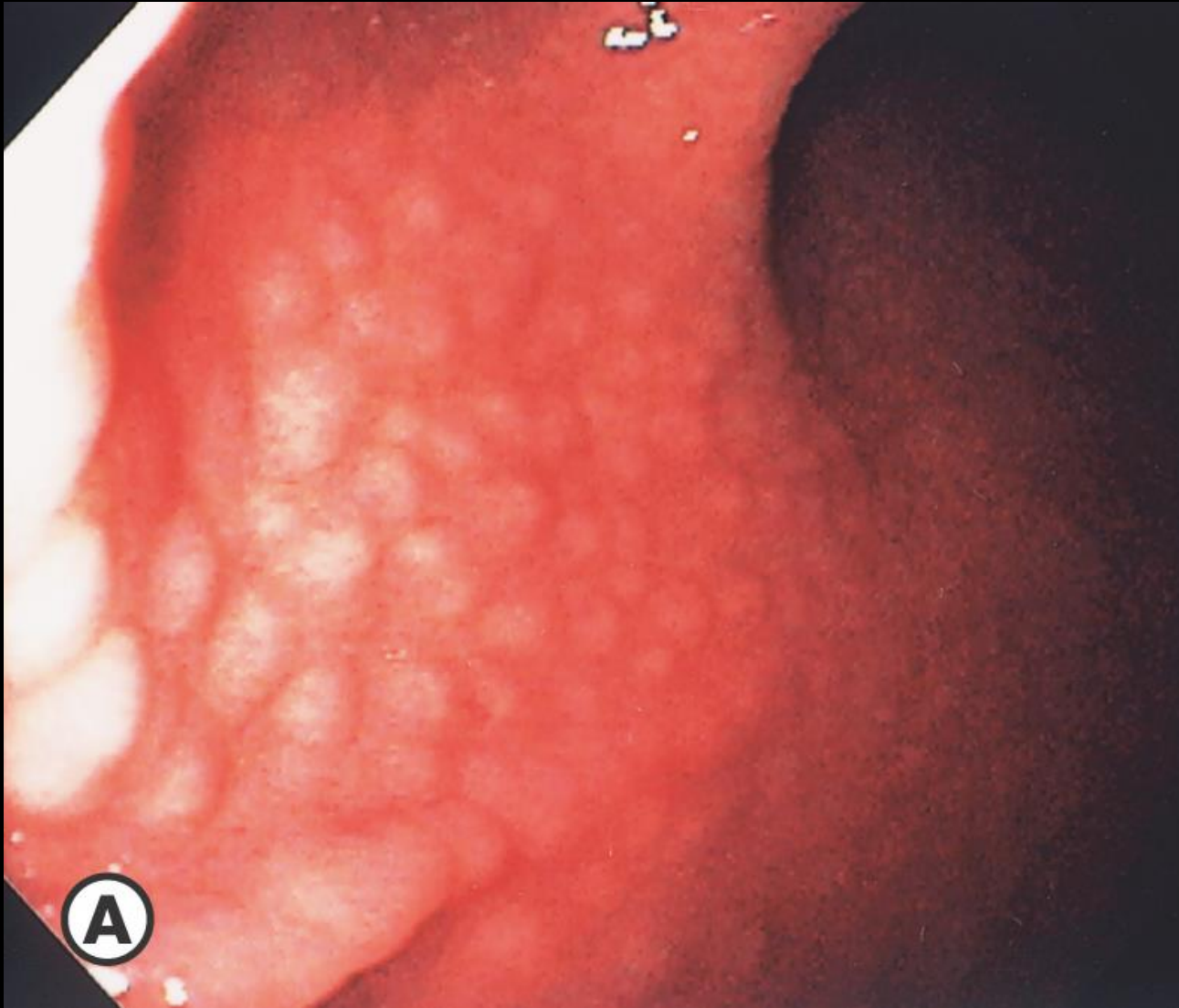


생검겸자

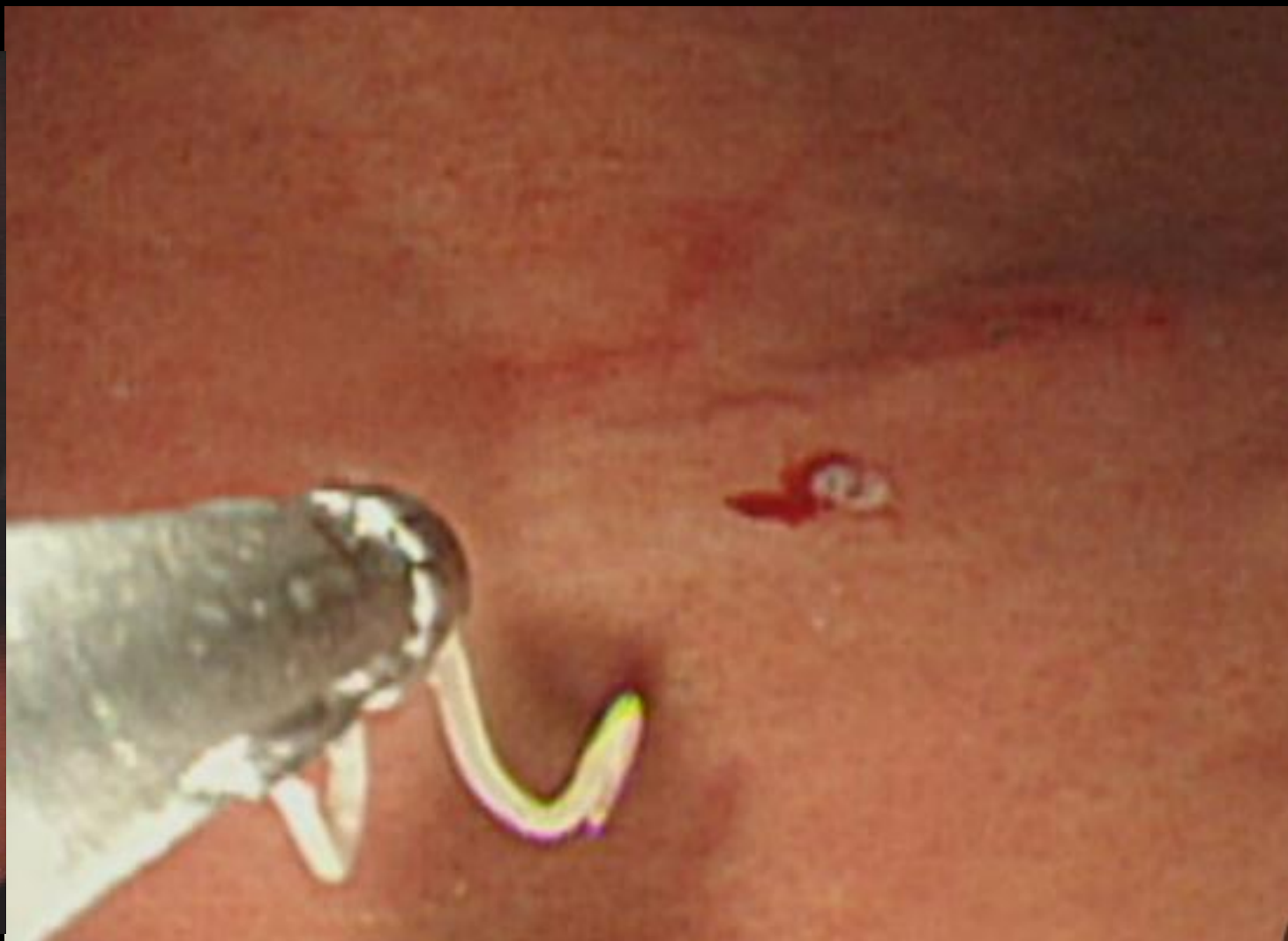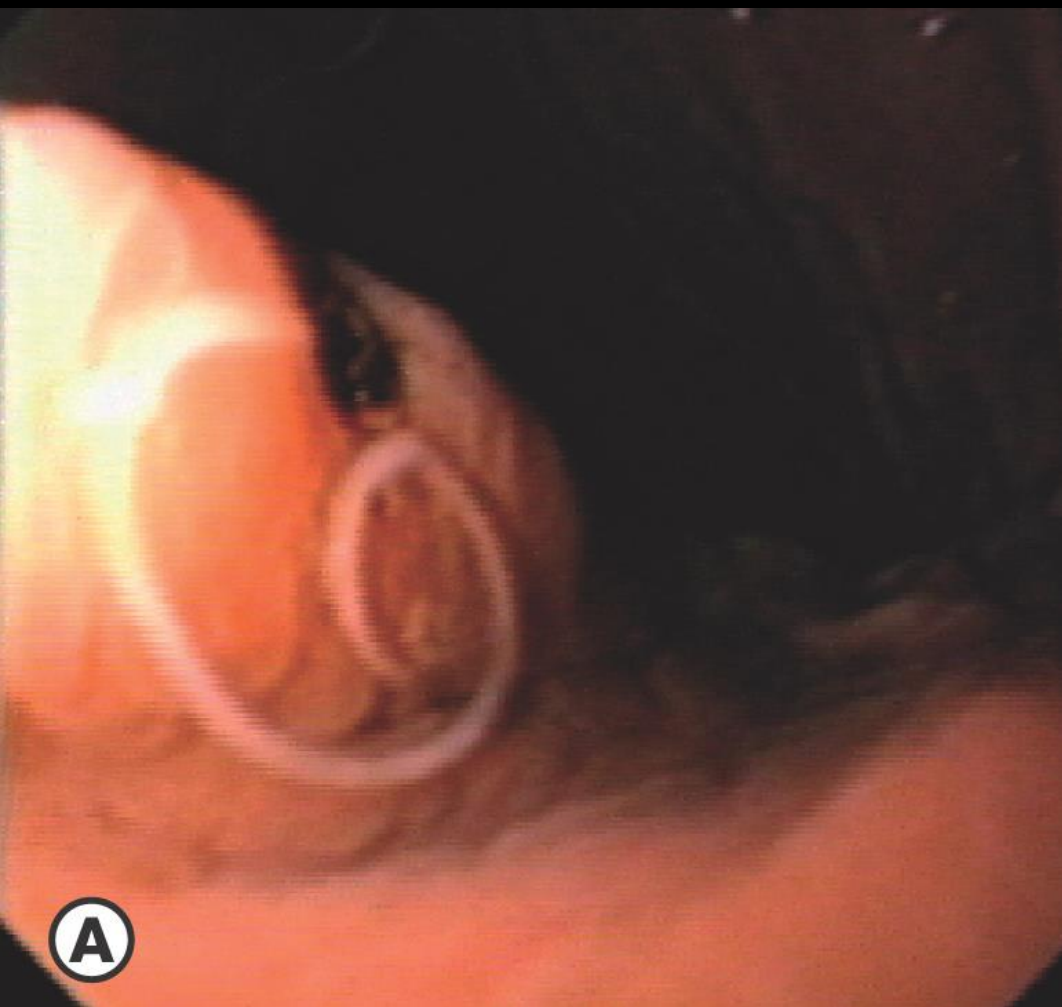


내시경스코프의 굽기

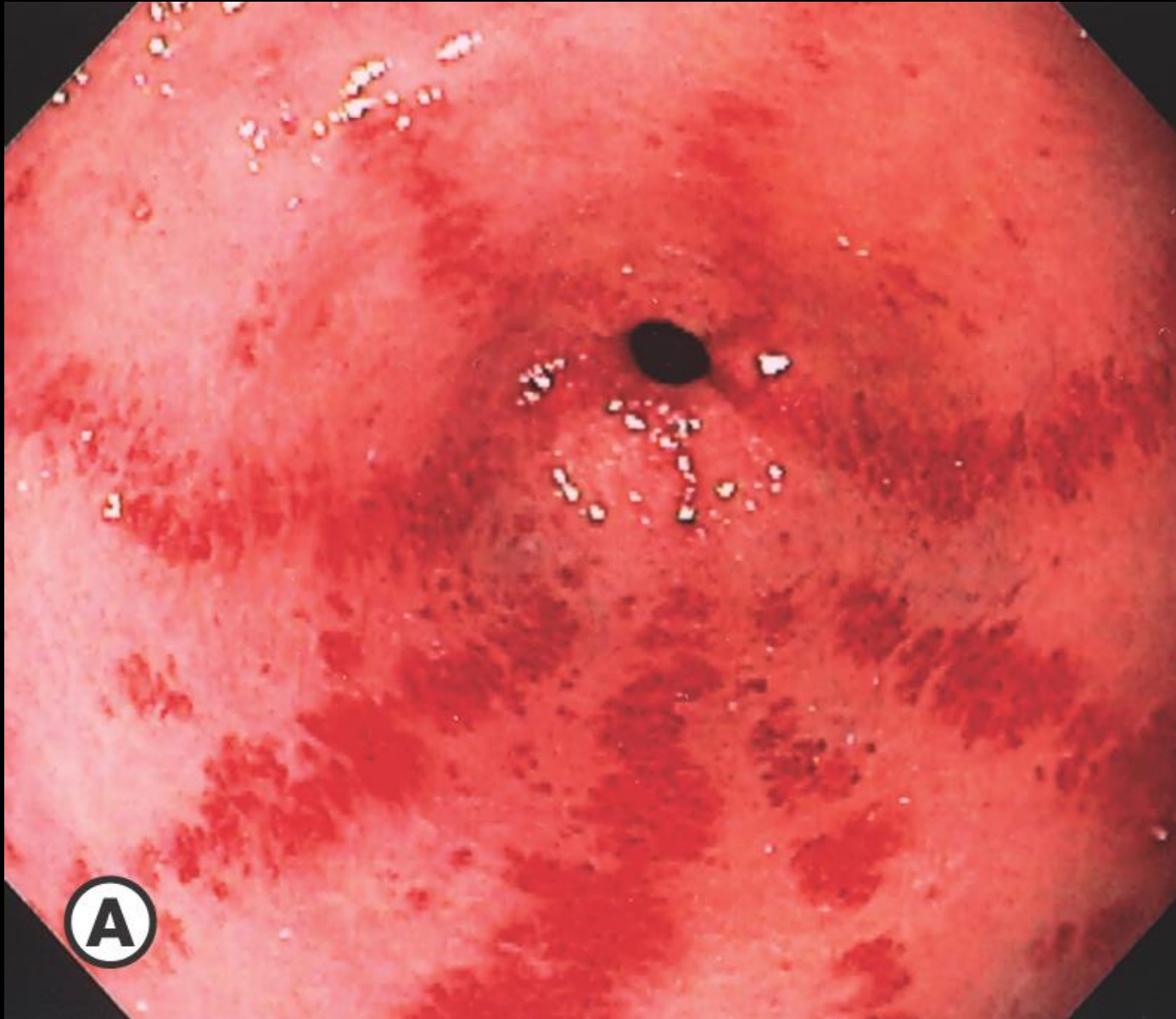증례- “Goose skin appearance” lymphofollicular gastritis

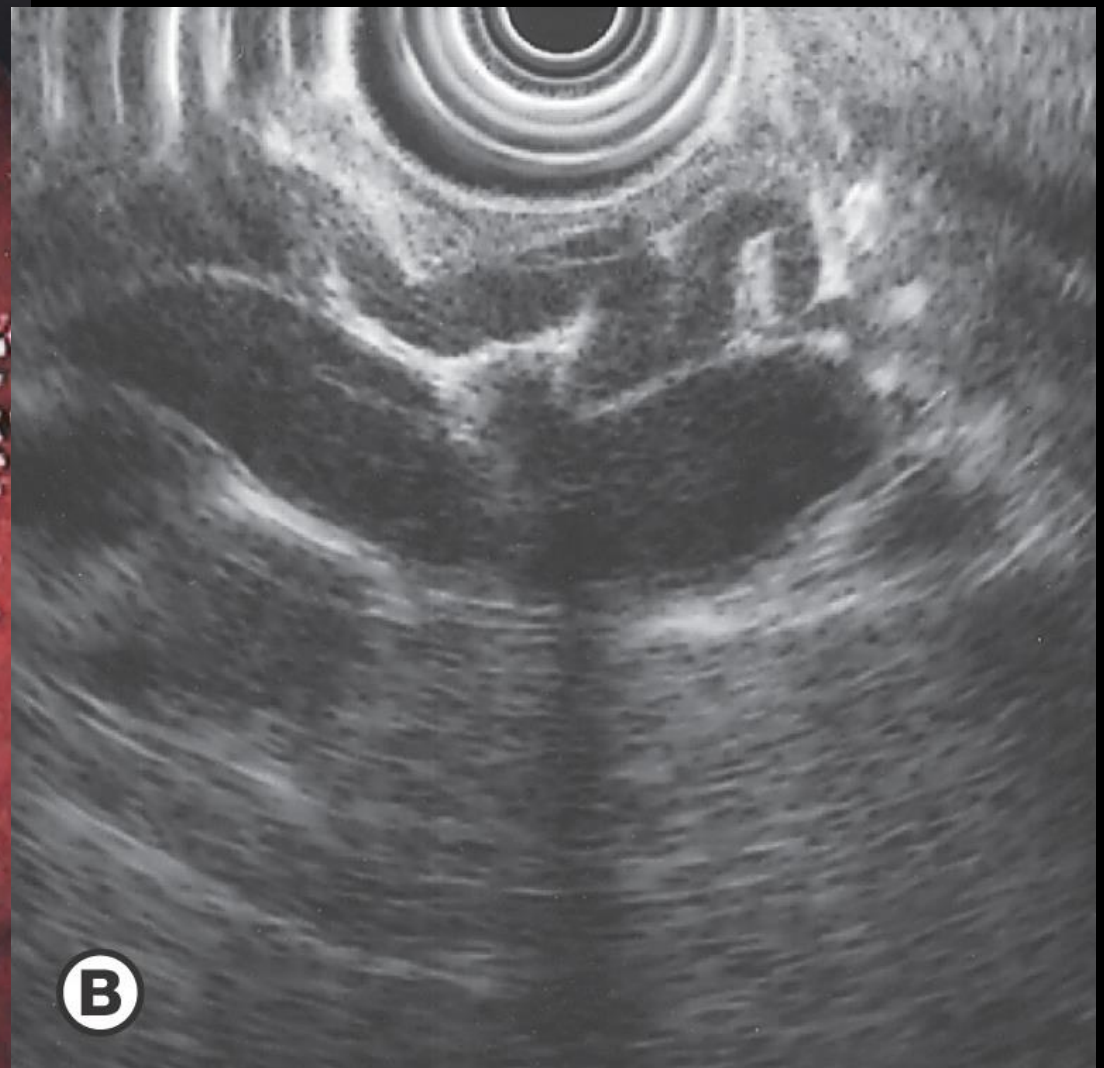
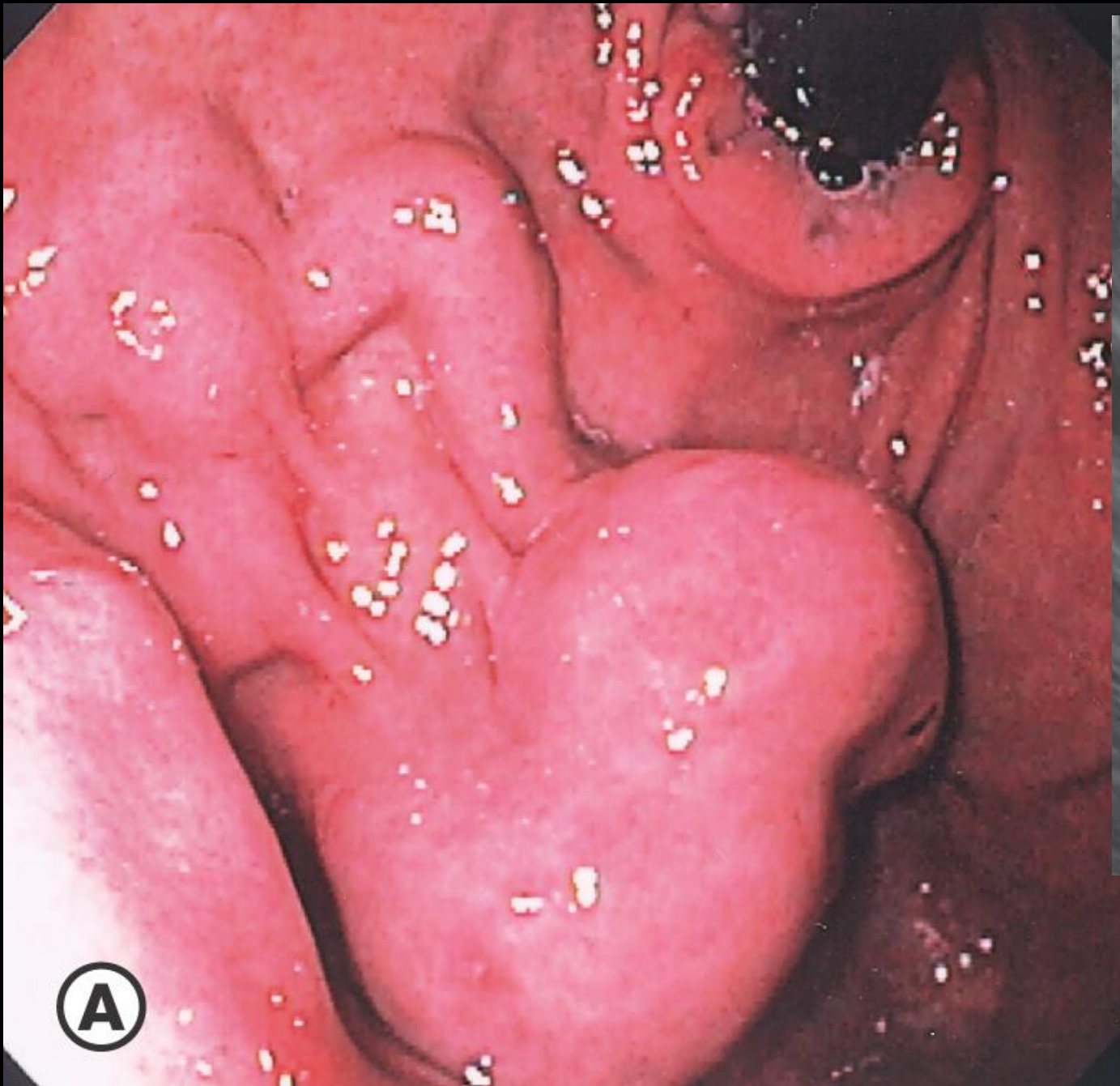


증례-고래회충, 아니사키스



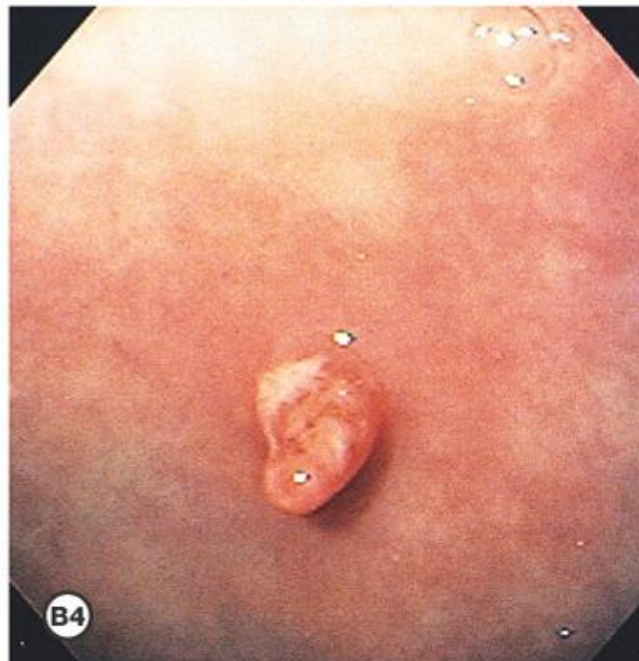
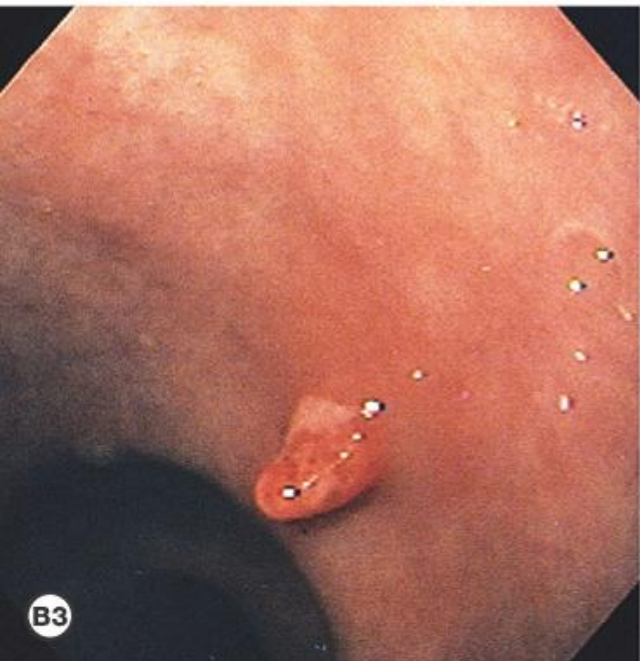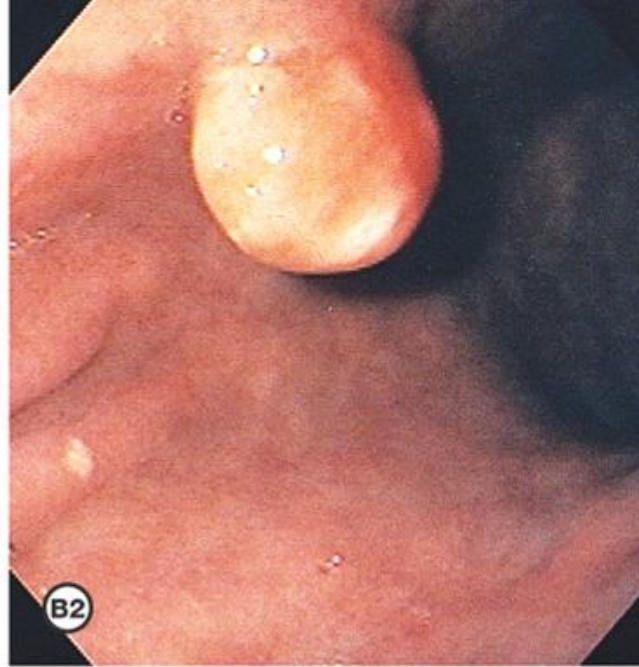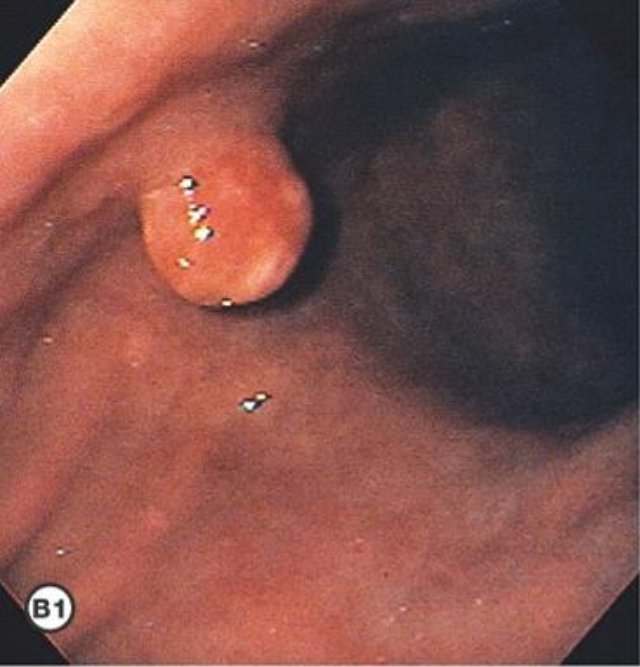
증례- Vascular ectasia

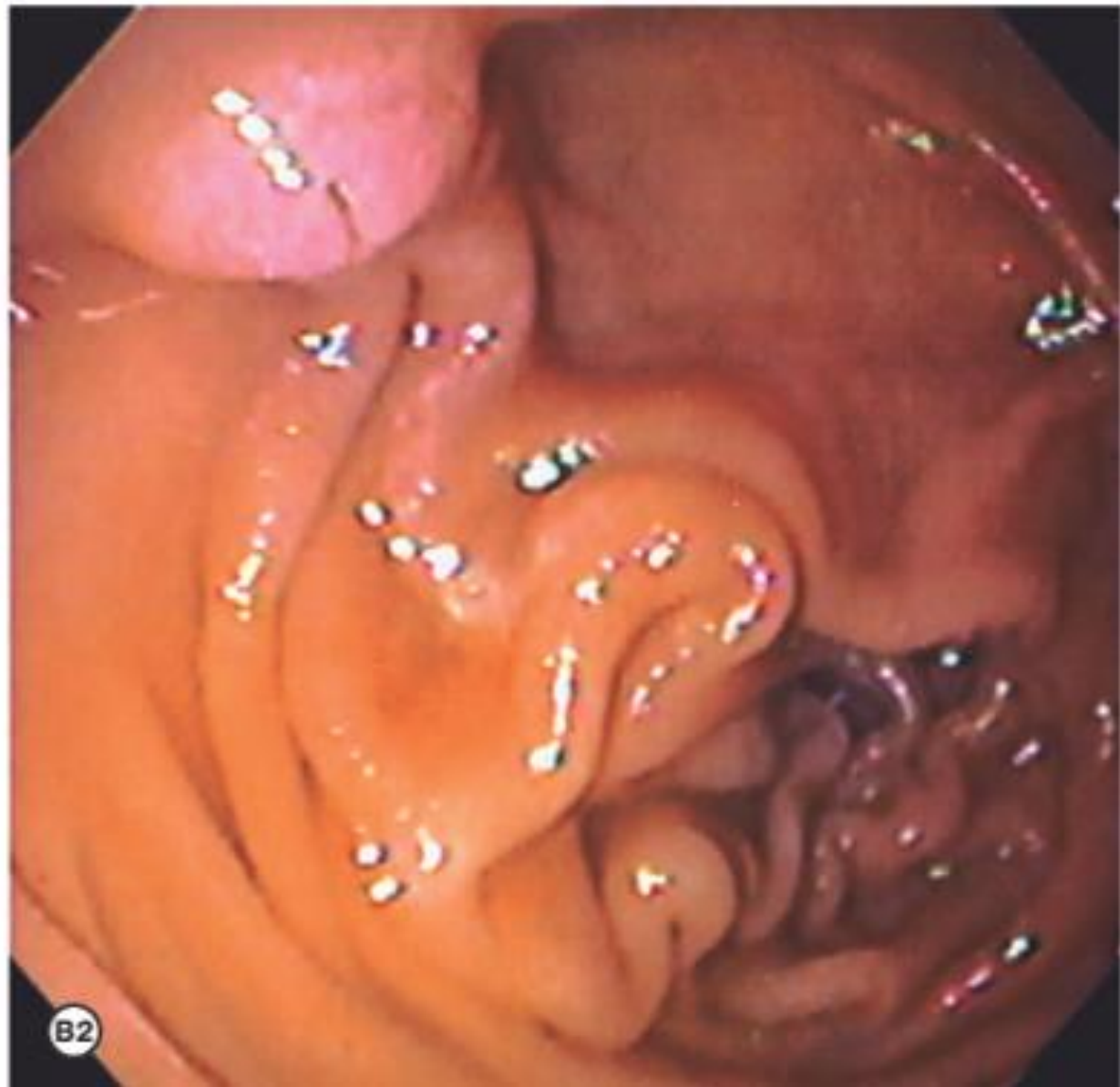
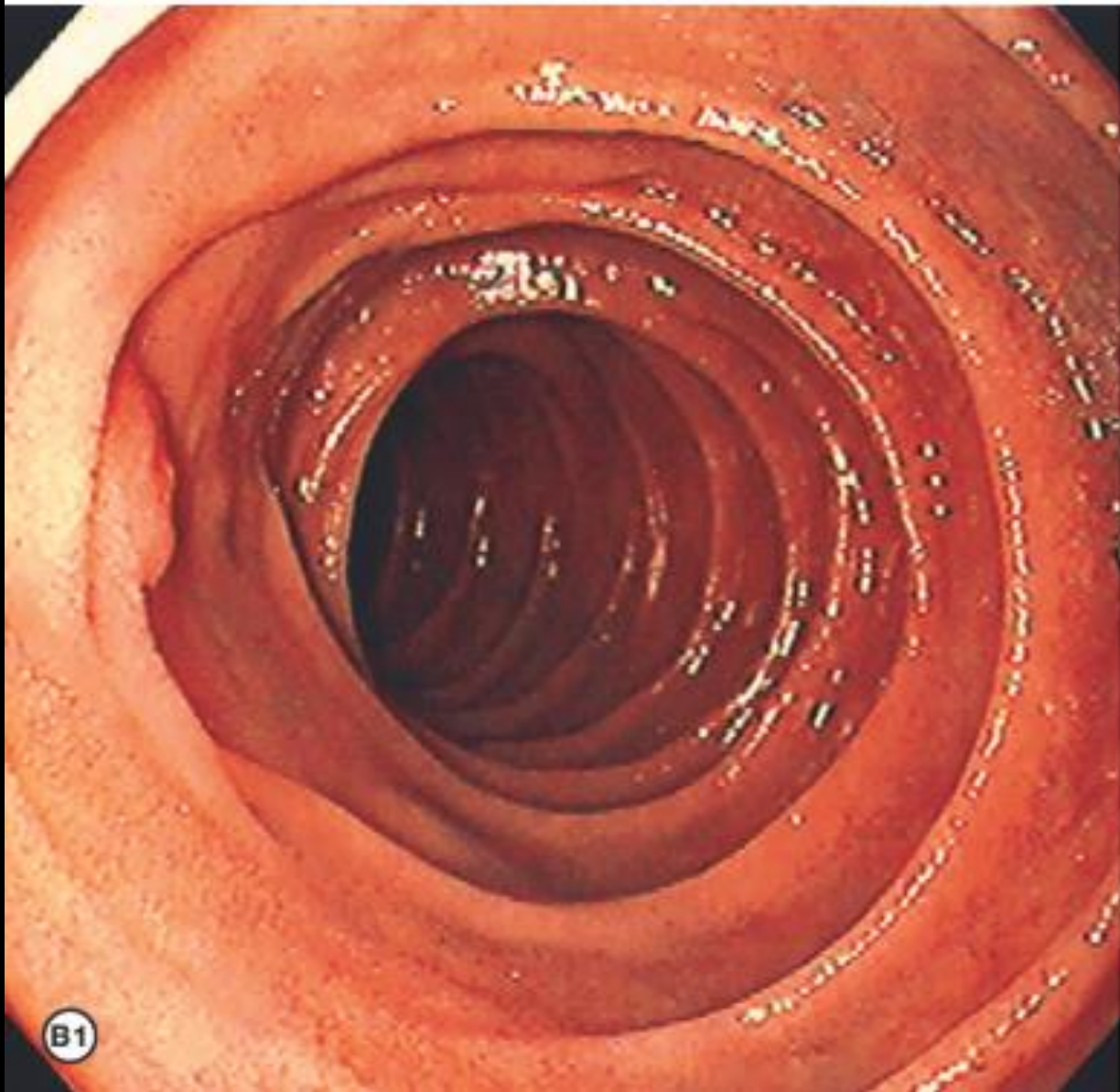




증례-Cardiac varix

염증성 용종





증례- Chronic gastritis with hp infection

